

Genetic Therapy for a Respiratory Virus Atrocity Under Glass

Robert W. Chandler, MD MBA

Summary:

Dr. Burkhardt is one of eight international pathologists, physicians and scientists who were asked to perform a second autopsy requested by friends and family of the deceased who were not satisfied with the results of the first autopsy.

30 autopsies and 3 biopsies were evaluated; 15 cases with routine histopathology (Step 1), 3 with advanced methods (Step 2), and some the remaining 15 are included as illustrative cases.

The Step 1 group included 8 women and 7 men aged 28-95 (average 69).

Death occurred 7 days to 180 days following the first or the second Spike Mediated Gene Therapy (SMGT) with Comirnaty in 8, Moderna in 2, AstraZeneca in 2, Janssen in 1 and Unknown in 2.

Place of death was known in 17 cases:

9 Non hospital: 5 at home, 1 on the street, 1 in a car, 1 at work, 1 in an elder care facility
8 Hospital: 4 ICU, 4 in hospital < 2 days

Special stains were used to identify Spike and Nucleocapsid Proteins with the following differential:

COVID-19 (C-19) = + Spike + Nucleocapsid
SMGT = + Spike - Nucleocapsid.

Causation by SMGT: Very probable in 5 cases, probable in 7, unclear in 2 and no connection in 1.

Lesions were on multiple organs: including Brain, Heart, Kidney, Liver, Lungs, Lymph Node, Salivary Gland, Skin, Spleen, Testis, Thyroid, Vascular.

Lymphocyte Infiltration, present in 14 of 20 cases (70%), was a common feature and involved multiple organs. Case 19 had at least five different organs involved. CD3+ Lymphocytes were dominant.

The Vascular System was targeted by Lymphocyte Infiltration in 7 (35%) of the cases and included sloughing endothelium, destruction of the vessel wall, hemorrhage, and thrombosis.

A condition called Lymphocyte Amok was described: Lymphocyte accumulation in non-lymphatic organs and tissues that might develop into Lymphoma.

Five cases of unknown foreign material in blood vessels were identified. The favored explanation for origin of this material was aggregated Lipid Nanoparticles.

Multiple pathologic processes were involved: Apoptosis, Coagulopathy, Clotting / Infarction, Infiltration/Mass Formation, Inflammation, Lysis, Necrosis and Neoplasia.

Rölgen, et. al. [https://www.cell.com/cell/fulltext/S0092-8674\(22\)00076-9](https://www.cell.com/cell/fulltext/S0092-8674(22)00076-9) found that C-19 depleted Lymphatic Germinal Centers (LGCs) whereas SMGT stimulated them suggesting a possible origin of “Hunter/Killer” CD3+ Lymphocytes that are attracted to certain tissues, particularly the Vascular system.

An expanded program of autopsy following SMGT is recommended in order to further understand the actions of SMGTs and to help formulate new treatments for the constellation of pathology associated with such drugs.

Burkhardt Group Conclusions:

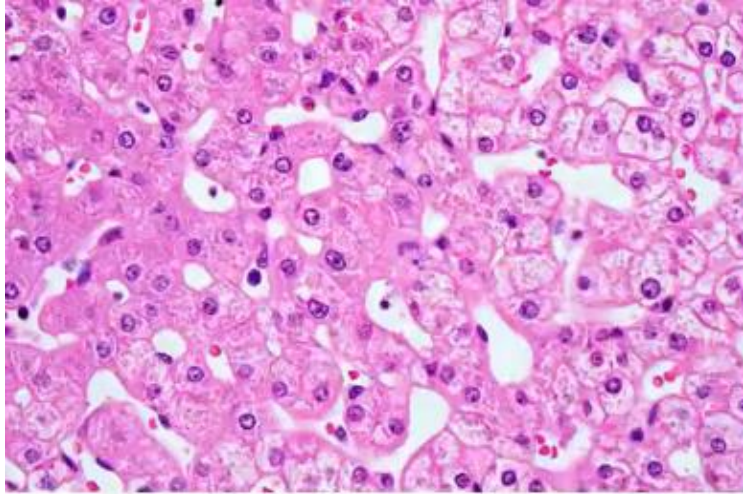
- 1. Histopathologic analyses show clear evidence of vaccine-induced autoimmune-like pathology in multiple organs.**
- 2. That myriad adverse events deriving from such auto-attack processes must be expected to very frequently occur in all individuals, particularly following booster injections.**
- 3. Beyond any doubt, injection of gene-based COVID-19 vaccines place lives under threat of illness and death.**
- 4. We note that both mRNA and vector-based vaccines are represented among these cases, as are all four major manufacturers.**

Histopathology

This report is the first in a series in which harms from the Lipid Nanoparticle Messenger Ribonucleic Acid therapeutics and other Spike mediated products will be examined from the point of view of the pathologist, a medical doctor that studies specimens obtained from removal of tissue from living persons, bulk resection or biopsy, or after death.

The purpose of such examinations is to make or confirm a diagnosis and provide a basis to determine causation of tissue mass or cause of death. Histopathology refers to the study of abnormal tissues.

Tissues are examined using careful inspection of specimens with the naked eye followed by examination by light microscopy employing a variety of different stains to highlight important features of cells, tissues and organs. A common stain used is Hematoxylin and Eosin which stains nuclei blue, cytoplasm pink or red, collagen fibers pink and muscles red.



Pathologists display sections prepared with H & E along with the magnification used such as 40 times (40X) or 100 times (100X) magnification.

Immunohistochemical Stains for Covid-19 and Spike Mediated Therapy

Special stains are vital to the identification of certain histopathology such as cases involving Spike mediated therapeutics. These examinations require special stains as outlined by Dr. Burkhardt whose specimens and lecture notes will be the subject of this first report in this series.

Dr. Burkhardt discusses below the necessary immunohistochemistry staining techniques necessary to differentially diagnose cell/tissue damage/organ from Covid-19, SARS-CoV-2 or something else as well as specific cell types of interest such as T-lymphocytes and monocytes,

Immunohistochemistry to detect vaccine-induced spike protein expression

Prof. Dr. A. Burkhardt

<https://doctors4covidethics.org/notes-and-recommendations-for-conducting-post-mortem-examination-autopsy-of-persons-deceased-in-connection-with-covid-vaccination/>

- Use anti-SARS-COV-2 spike protein/S1 antibodies to test for presence of spike protein in tissue samples. Always include myocardium and spleen tissue samples
- If spike protein is detected, use anti-nucleocapsid antibody to examine expression of SARS-COV-2 nucleocapsid: presence of nucleocapsid indicates viral “breakthrough” infection, absence of nucleocapsid supports vaccine-induced spike protein expression
- Perform positive and negative controls using vaccine-transfected and non-transfected cell cultures.

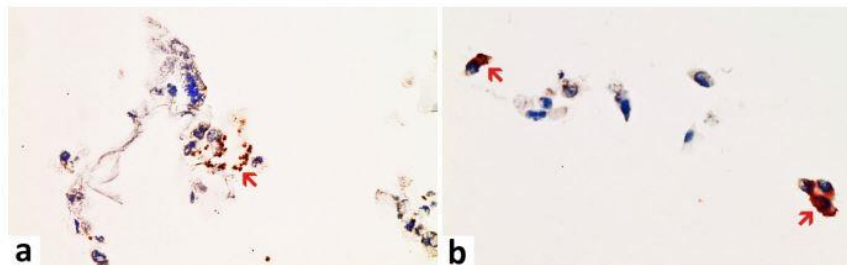
Differential Staining to identify CD3 and CD68 cells and to Differentiate Covid-19 from Spike Inducing Drugs

Covid-19 = Spike stain + Nucleocapsid stain +

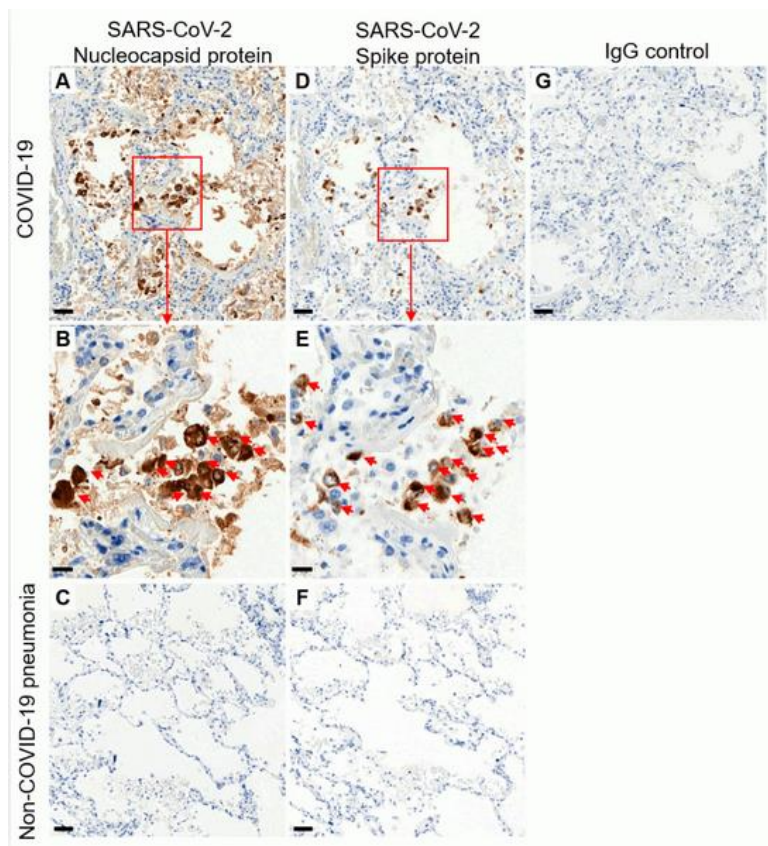
LNP/mRNA = Spike stain + Nucleocapsid stain -:

Table 1. Primary antibodies used for immunohistochemistry. Tissue sections were incubated 30 min with the antibody in question, diluted as stated in the table.

Target Antigen	Manufacturer	Clone	Dilution	Incubation Time
CD3 (expressed by T-Lymphocytes)	cytomed	ZM-45	1:200	30 min
CD68 (expressed by monocytic cells)	DAKO	PG-M1	1:100	30 min
SARS-CoV-2-Spike subunit 1	ProSci	9083	1:500	30 min
SARS-CoV-2-Nucleocapsid	ProSci	35-720	1:500	30 min



a. Spike, red arrow. B. Nucleocapsid, red arrow.



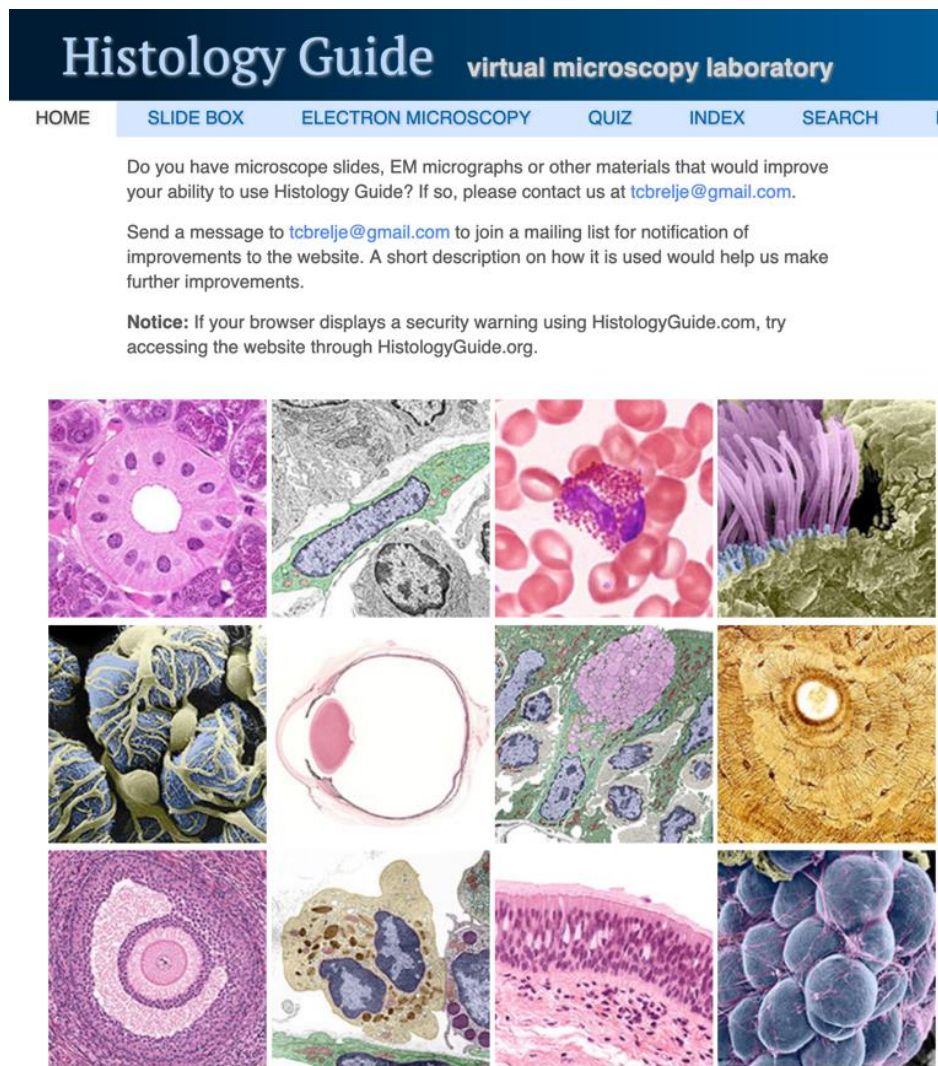<https://www.prosci-inc.com/>

Without these special stains and without an exhaustive search of the specimens no autopsy should be considered complete.

The internet is an excellent source for examples of both normal and pathological cells, tissues and organs.

A useful guide to have available when looking at the photomicrographs to follow is the Histology Guide at,

<https://histologyguide.com/>



This internet tool can be used to examine normal histology and compare it to the histopathology seen in Dr. Burkhardt's slide deck which has been integrated with the transcription from his lecture 02/05/2022

Autopsy-Histology-Study on Vaccination-Associated Complications and Deaths¹

Understanding Vaccine Causation Conference 2/05/2022
World Council for Health

Dr. Arne Burkhardt
Pathologist
Reutlingen, Germany

“Dr. Arne Burkhardt, born in 1944 in Germany, a pathologist with more than 40 years diagnostic and teaching experience at the Universities of Hamburg, Bern, and Tübingen. He is the author of more than 150 original publications in international journals, currently engaged in autopsy studies of persons dying after taking the Covid vaccine.” **Shabhan Palesa Mohamed**



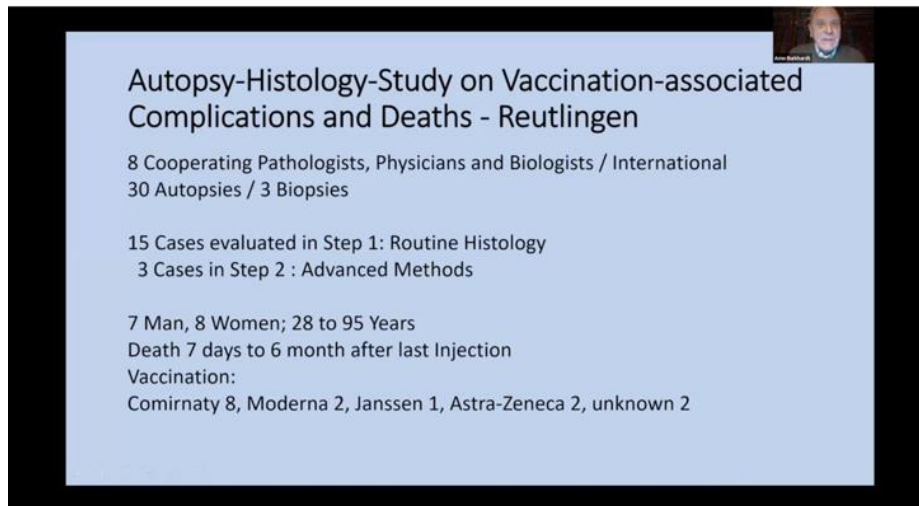
<https://worldcouncilforhealth.org/multimedia/uvc-arne-burkhardt/>

Dr. Burkhardt I think it’s very, very, important to have an international communication on this subject, because last year in May, April, I was confronted with some relatives of persons who died after vaccination. And I tried to establish a national registry of these persons dying.

And I tried to get autopsies done in these persons, but the national associations of pathology here didn’t reply to this request by myself. So, when relatives continued to ask me, “Where can I get some solution to this problem?” finally, I said, “I can examine these organ probes that have been taken during autopsy, and we can try to get some other pathologists sent.”

¹ Dr. Burkhardt’s Slide Deck was reproduced here and was integrated with the text derived from notes compiled from the voice recognition transcript with limited editing for readability with no intention to make substantive changes.

These are the most relevant data on our study. We have **eight cooperating pathologists, physicians, biologists;** and they are internationally from Germany and other European countries, and also some outside of Europe.



Autopsy-Histology-Study on Vaccination-associated Complications and Deaths - Reutlingen

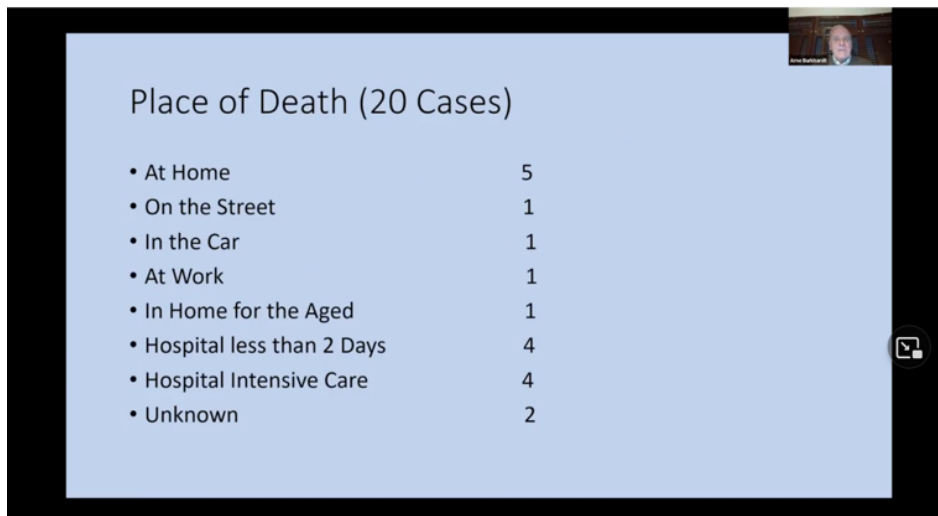
8 Cooperating Pathologists, Physicians and Biologists / International
30 Autopsies / 3 Biopsies

15 Cases evaluated in Step 1: Routine Histology
3 Cases in Step 2 : Advanced Methods

7 Man, 8 Women; 28 to 95 Years
Death 7 days to 6 month after last Injection
Vaccination:
Comirnaty 8, Moderna 2, Janssen 1, Astra-Zeneca 2, unknown 2

So, by now we have 30 autopsies and three biopsies from vaccinated persons. Fifteen cases have been evaluated in the step one that has reached Routine Histology. Three cases are in step two, Advanced Methods. I will explain what I mean by this.

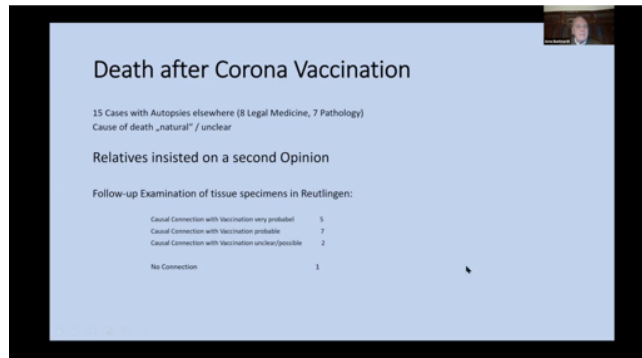
And, just to give you a rough Impression, it's seven men, eight women, 28 years to 95 years, death seven days to six months after the last injection and vaccination, the typical vaccinations that are used in Germany.



Place of Death (20 Cases)

• At Home	5
• On the Street	1
• In the Car	1
• At Work	1
• In Home for the Aged	1
• Hospital less than 2 Days	4
• Hospital Intensive Care	4
• Unknown	2

So, one important fact is that most of these persons that we examined have not died in the hospital, but at home, on the street, in the car. And that is very important, because, in these cases, we can exclude that there is interference with therapeutical measures like artificial respiration and things like that. So, only four were in intensive care medicine before they died.



We had **15 cases** with autopsy elsewhere which we examined in step one. And all of these 15 cases were classified by the pathologist of legal medical persons who made the autopsy as **natural and unclear**. And the relatives insisted on a second opinion. And we, in Reutlingen, in our group, looked at the specimens of the organs that were taken.

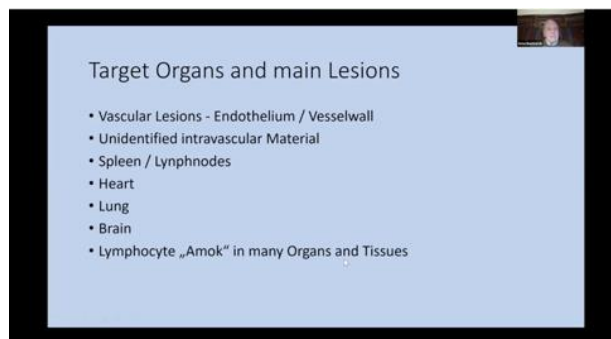
Burkhardt Series: 15 Cases in Step 1

Case #	Gender	Age	Drug	Days from Last Inj to Death
Case 1	Female	82	Moderna 1 & 2	37
Case 2	Male	72	Pfizer 1	31
Case 3	Female	95	Moderna 1 & 2	68
Case 4	Female	73	Pfizer 1	Unknown
Case 5	Male	54	Janssen 1	65
Case 6	Female	55	Pfizer 1 & 2	11
Case 7	Male	56	Pfizer 1 & 2	8
Case 8	Male	80	Pfizer 1 & 2	37
Case 9	Female	89	Unknown 1 & 2	180
Case 10	Female	81	Unknown 1 & 2	Unknown
Case 11	Male	64	AstraZeneca 1 & 2	7
Case 12	Female	71	Pfizer 1 & 2	20
Case 13	Male	28	AstraZeneca 1 Pfizer 2	28
Case 14	Male	78	Pfizer 1 & 2	62
Case 15	Female	60	Pfizer 1	23

Average Age: 69, 28-95 Time from Injection to Death Average: 45 Days, 7-180

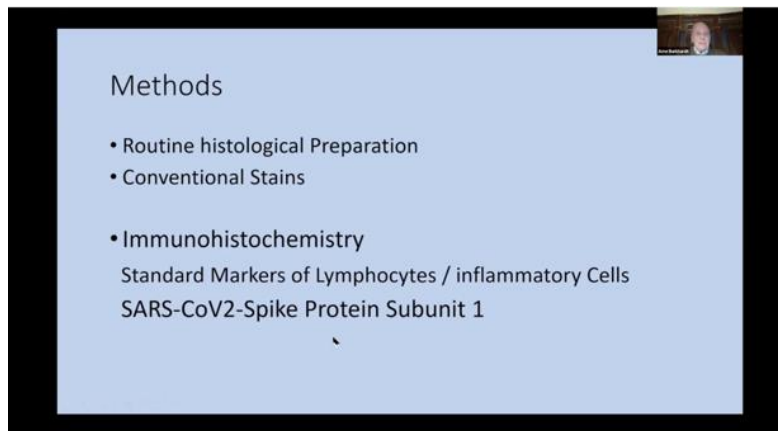
Our follow-up gave **very probable correlation with the vaccination in five cases, probable in seven, unclear/possible in two, and no connections** with only minimal changes we saw in **one case**.

So, what were the organs where we saw lesions? The target organs and the main lesions in her (sic) space, vascular lesions. Not only to the small vessels, the endothelium, but also to large vessel walls, to the muscular and elastic wall components.



1. In five cases, **we found unidentified, intervascular material that might stem from the vaccination material**. Then

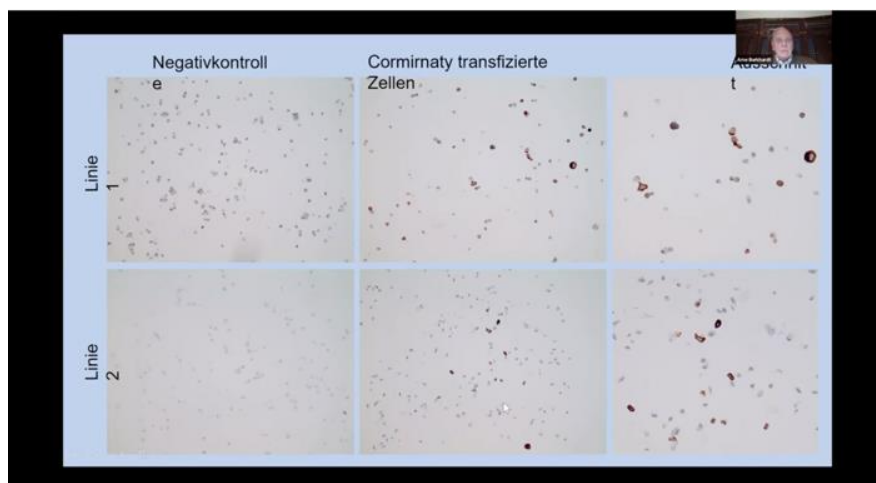
2. Spleen and
3. Lymph nodes had changes.
4. Heart,
5. Lung
6. Brain, and, finally, a phenomenon that we call
7. **Lymphocyte Amok**. That means that **we've found applications and nodular infiltration of lymphatic tissues and organs and tissues that are non-lymphatic.**



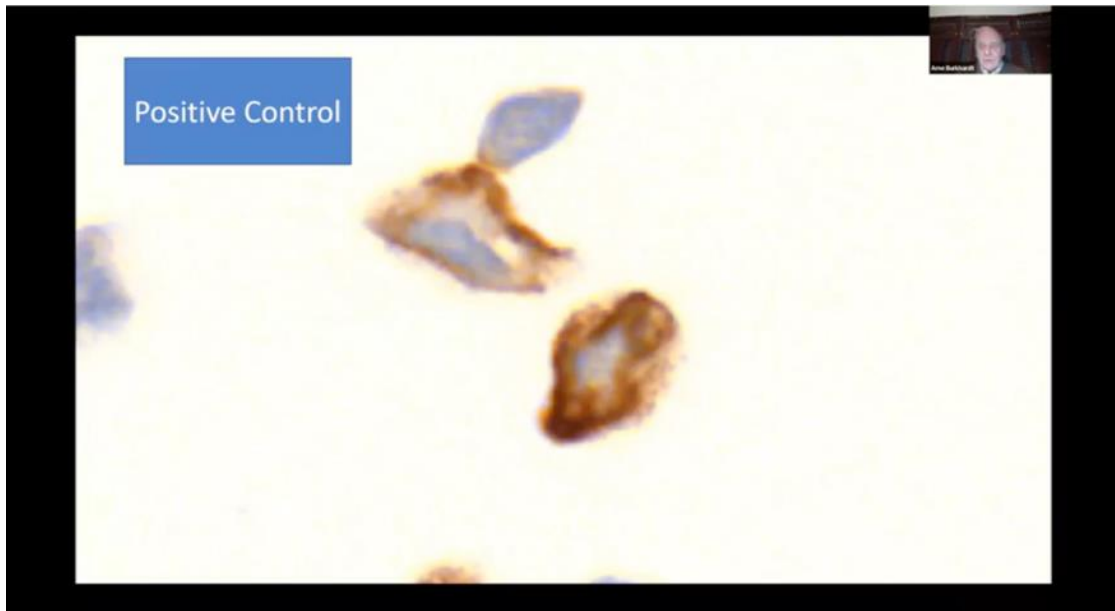
So, what are our methods?

1. First of all, routine histological preparation with conventional stain, and then
2. Immunohistochemistry first standard markers for lymphocytes/inflammatory cells.
3. But mostly this is one of the aims of this study, too, **we try to demonstrate the Spike protein in the organs and tissues that were damaged.**

And first of all, of course, we examine the **specificity of our antibody to a Spike protein**, and here a larger magnification. So, it seems to have a very high specificity for this Spike protein. And we did this in cell cultures



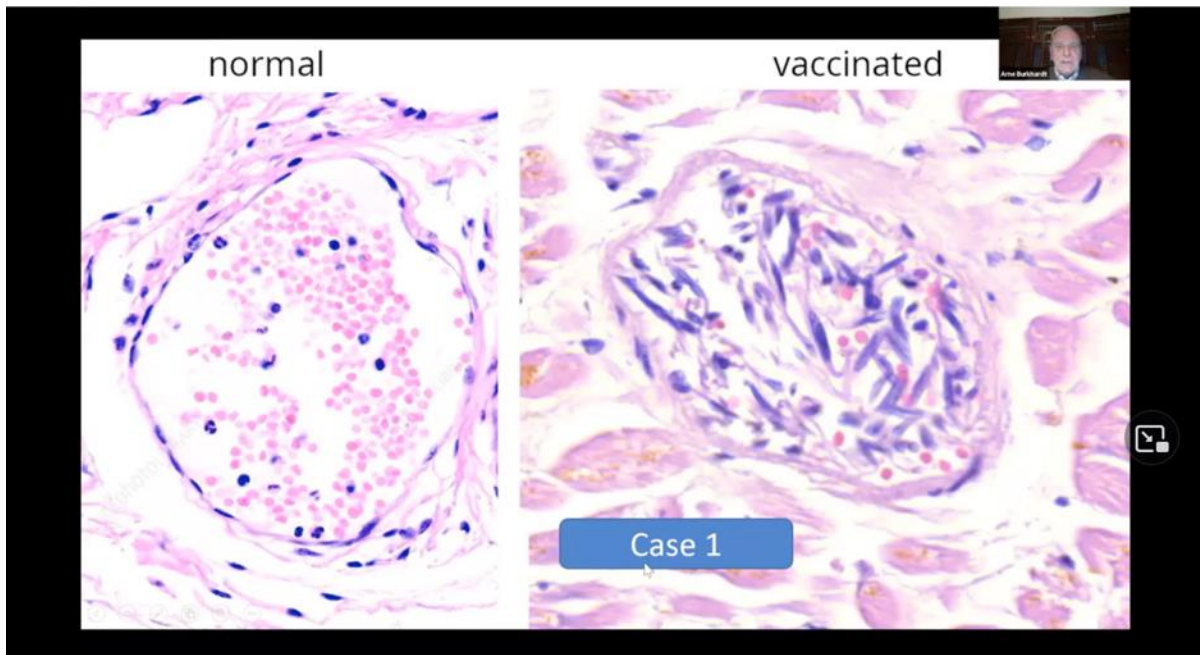
and you can see here net negative control, positive control.



And I will just show you a few examples of the tissue damage that I have listed before.

Blood Vessels, Endovasculitis, Perivasculitis and Vasculitis

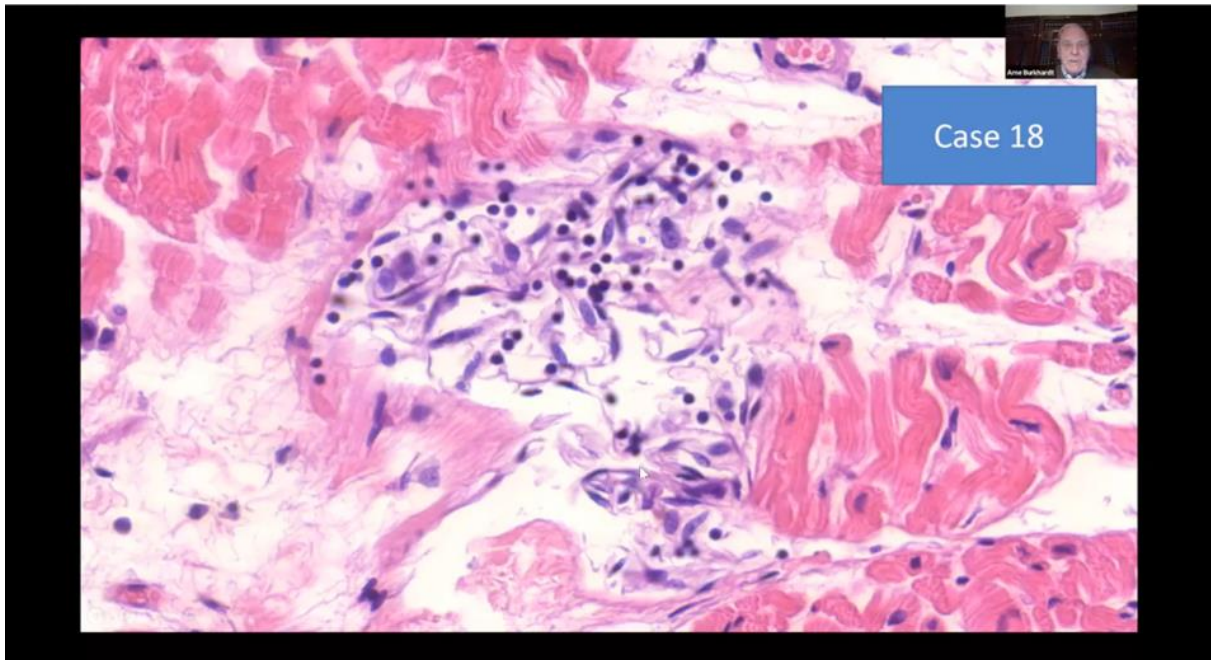
So here (*left*) you can see a normal, small vessel, and you can see the endothelium that is like a wallpaper and very small, elongated spindle cell nuclei.



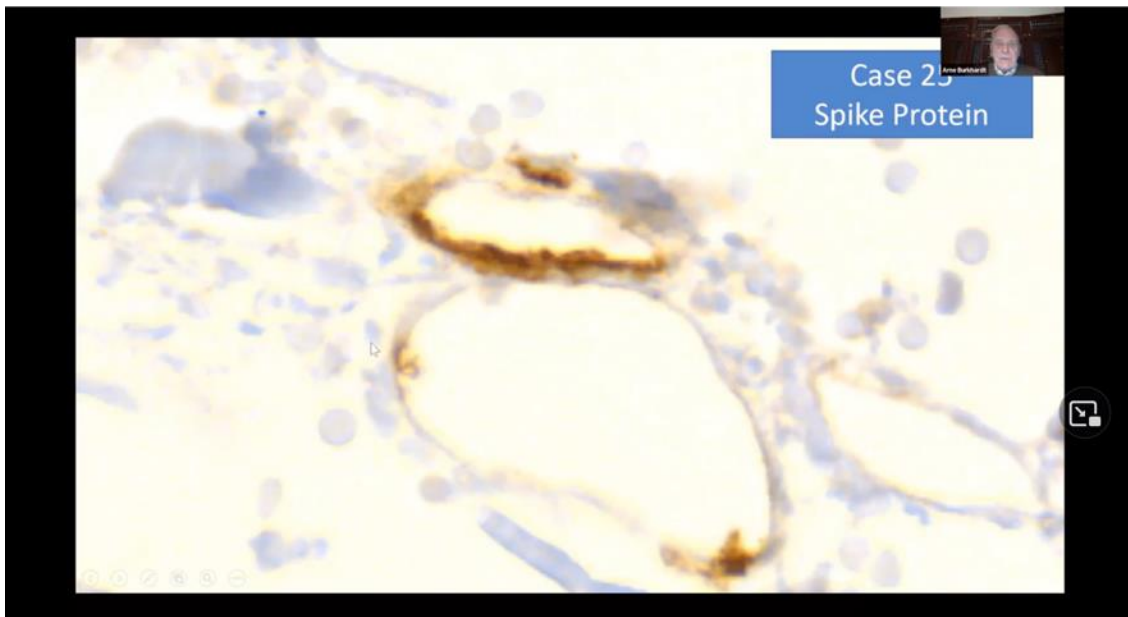
And here (*right*) in one of the cases, you can see that the

1. Endothelium is in the lumen. And it is in there mixed with

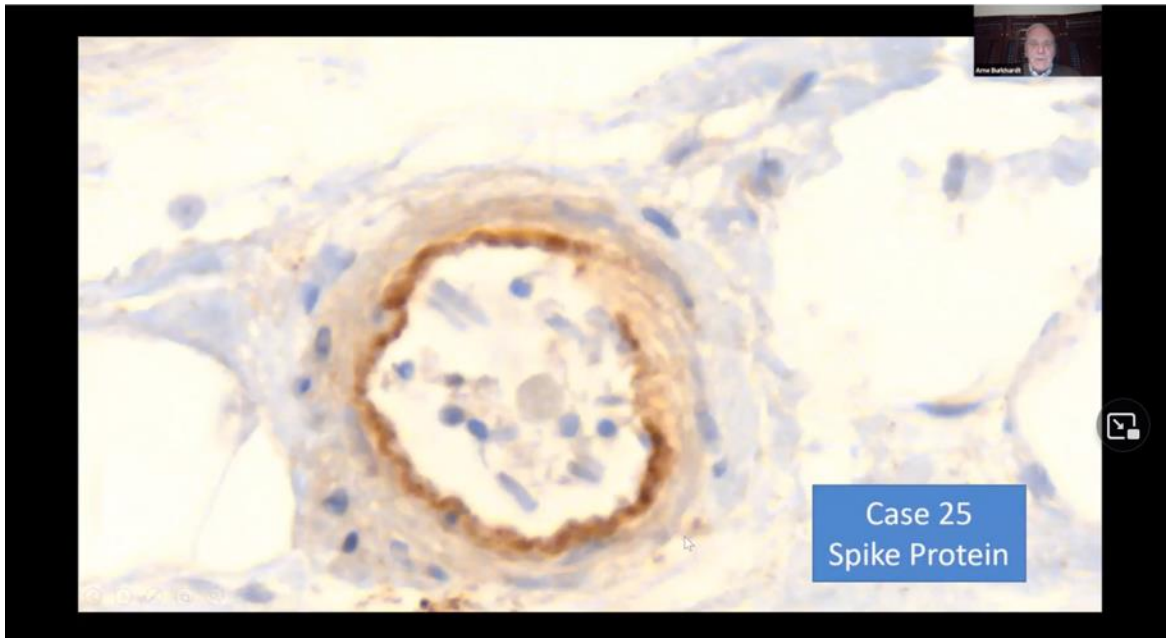
2. Lymphocytes and erythrocytes and the
3. Nuclei are swollen.



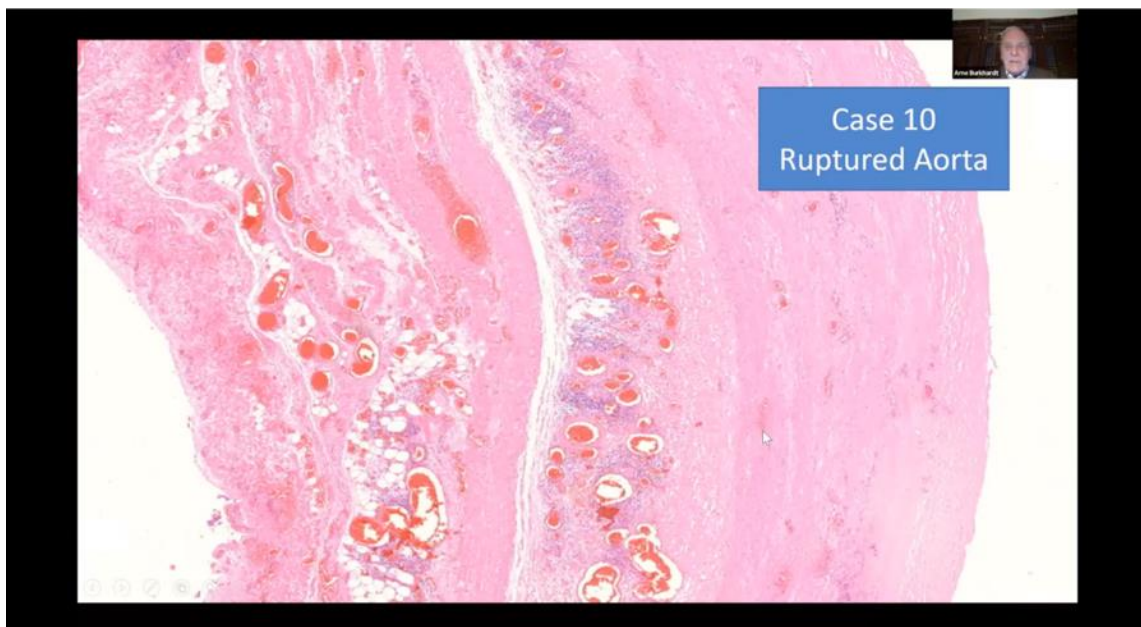
So, in some cases, the small vessels even are completely destroyed by inflammatory infiltrates, mostly lymphocytes. And this proves to me that it is an intravital reaction and not an autolytic phenomenon caused by degradation after death.



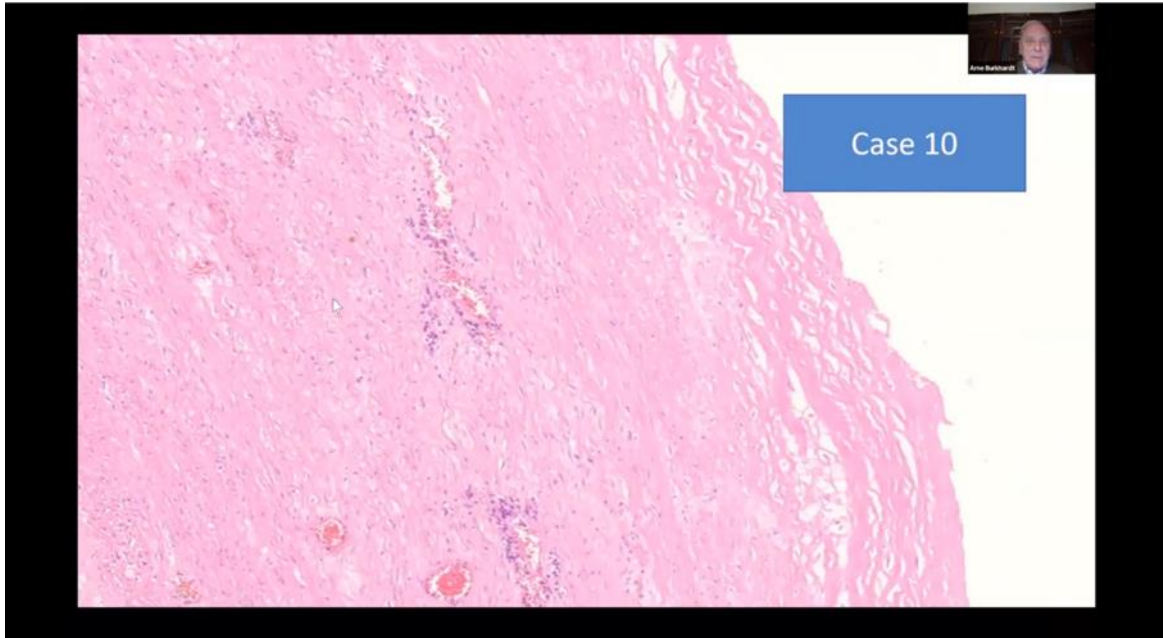
So, we get the Spike protein, immunohistochemistry on these cases, and we see, you see here a very marked and specific the mark of the endothelium in these patients. *Rust-color stain more extensive in the smaller vessel wall.*



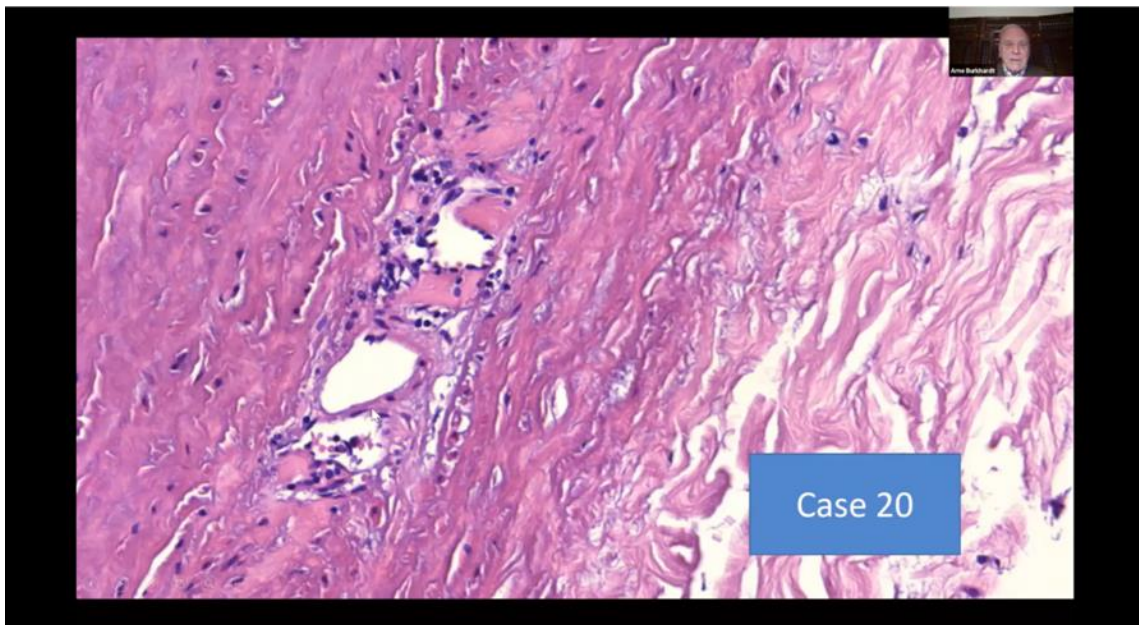
And not only in the small vessels, but also in the smaller arteries, you can see it in the inner part of the vessel. And you can see here there's decimated endothelial cells.



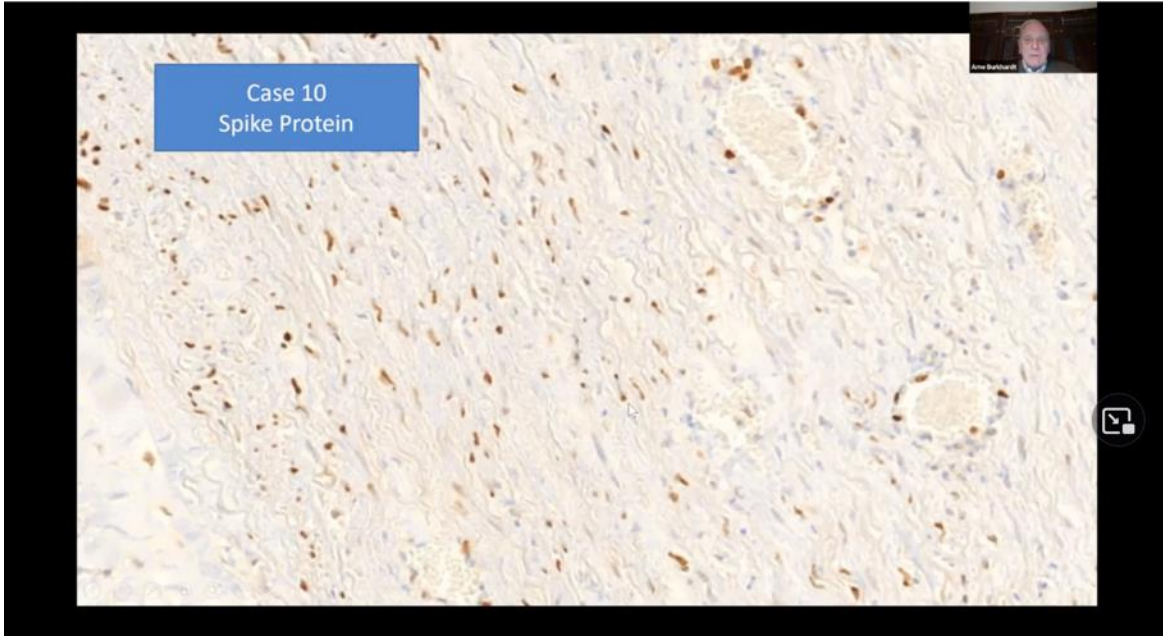
So, not as I said, not only the smaller vessels were affected, but also the **aorta** and the larger arteries and **two cases have died of a ruptured artery**. And, actually, we found arteriosclerotic changes; but, as you see here, it's not very pronounced. But you can see inflammatory changes around in the deep layers of this aorta, and also you can see some disturbance of structure of the smooth muscle and the elastic fibers.



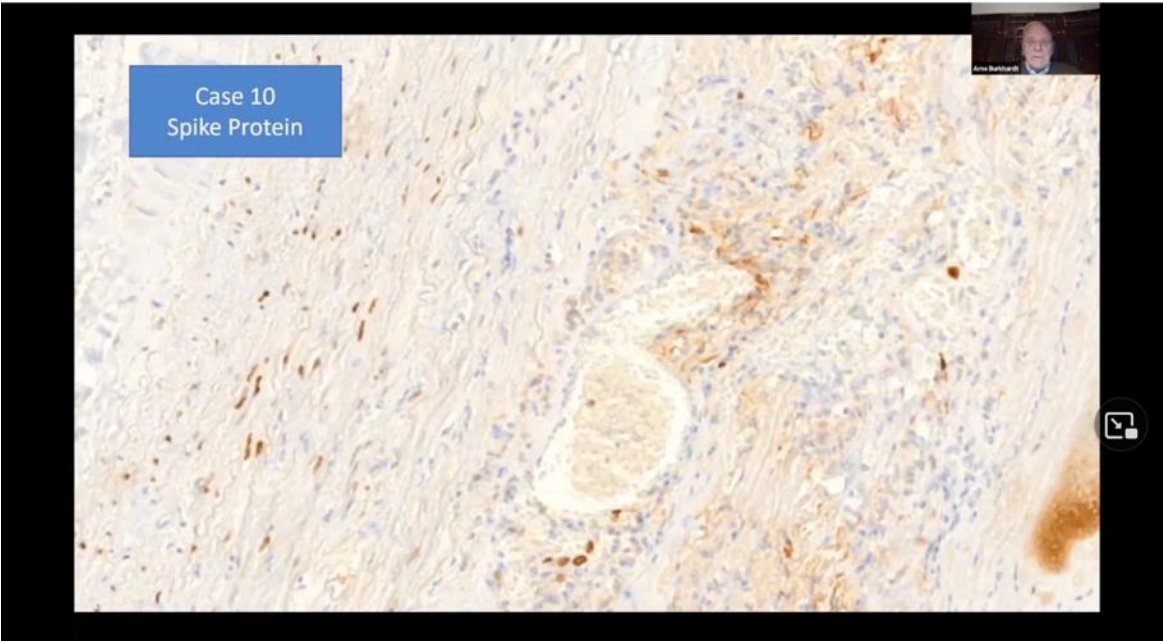
And if you have a higher magnification, you can see these small areas where the elastic fibers and smooth muscles are destroyed. And again, lymphocytic infiltration proving that it was an intravital process.



And here another case. We found it in, in five cases, so this cannot be a coincidence.



And we did the Spike protein *stain*, and you find a marked positive expression (*expression*) of Spike protein in the myofibroblasts of the arterial wall. This is the aorta.



And also in the vasa vasorum, you can see very strong expression of Spike protein in these areas. And this, I think, is a very important finding.

Vasculitis

Endovasculitis („Endothelitis“)	11 Cases
Endothelial swelling and desquamation, Focal lymphocytic Infiltration	(1,2,4,5,7,8,9,13,18,19,20)
Main Localisation: Heart, Lung	
Vasculitis /Perivasculitis	10 Cases (1,2,4,5,7,8,9,13,18,20)
Perivasculitis, lymphocytic Infiltration of Vasa vasorum	
Fokal Media-Necrosis and inflammatory Reaction	6 Cases (3,6,7,13,19,20)
With Thrombosis	2 Cases

Similar vascular lesions are caused by toxins – cytostatic drugs (Bleomycin) and Lathyrism – Role of Spike-Protein?

So how often did we see this vasculitis, this endovasculitis or some call it

1. **Endothelitis, in 11 cases with focal lymphocytic infiltration,** then
2. **Vasculitis paravasculitis in 10 cases,**
3. **Focal media-necrosis in six cases,** and
4. **Thrombosis** caused on this area in **two cases.**

Spleen and Liver

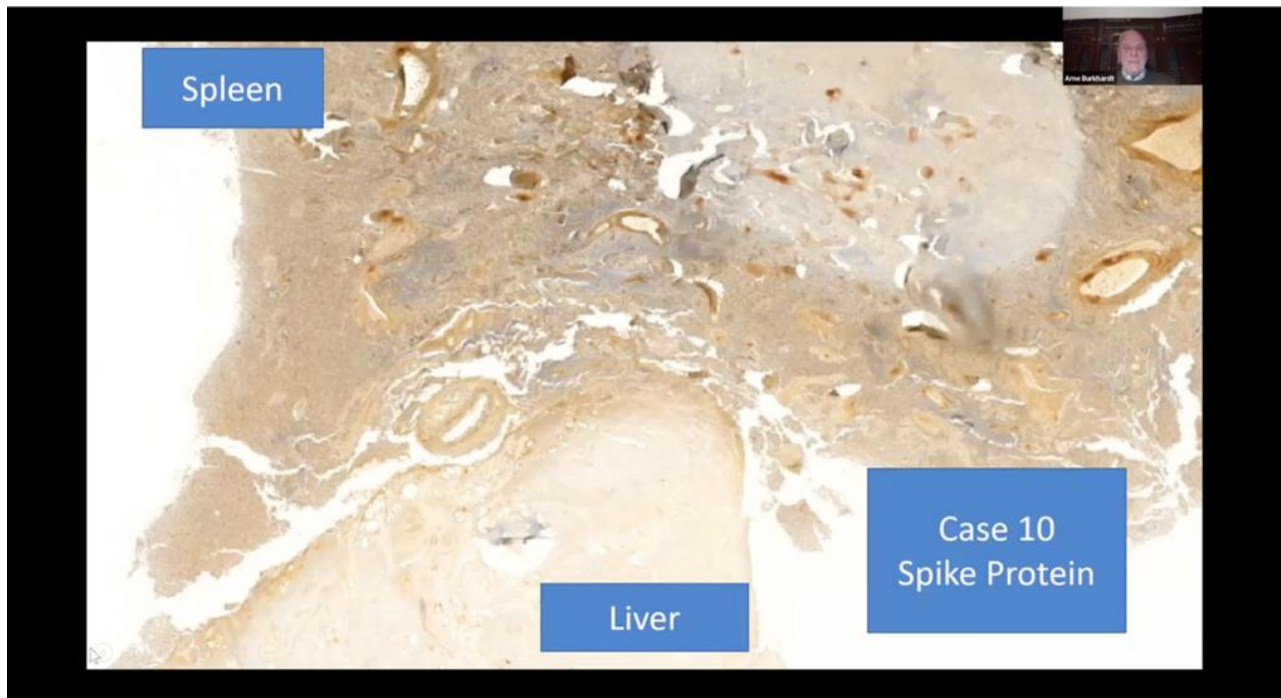So similar lesions are caused by toxins and drugs, cytostatic drugs, and in some food poisoning like lathyrism. And so, **we think also here a toxic element, the Spike protein might be the causative agent.**

SPLEEN

„Onion-Skin“ Arteriolitis of the Spleen Arteries
as seen in Autoimmundisease
(Lupus erythematodes)

Focal Destruction of follicular Arteries in the
Spleen with Prolapse of lymphatic follicular
Tissue into the Vessel (not seen before?)

Now another, other lesions that we saw in the spleen.

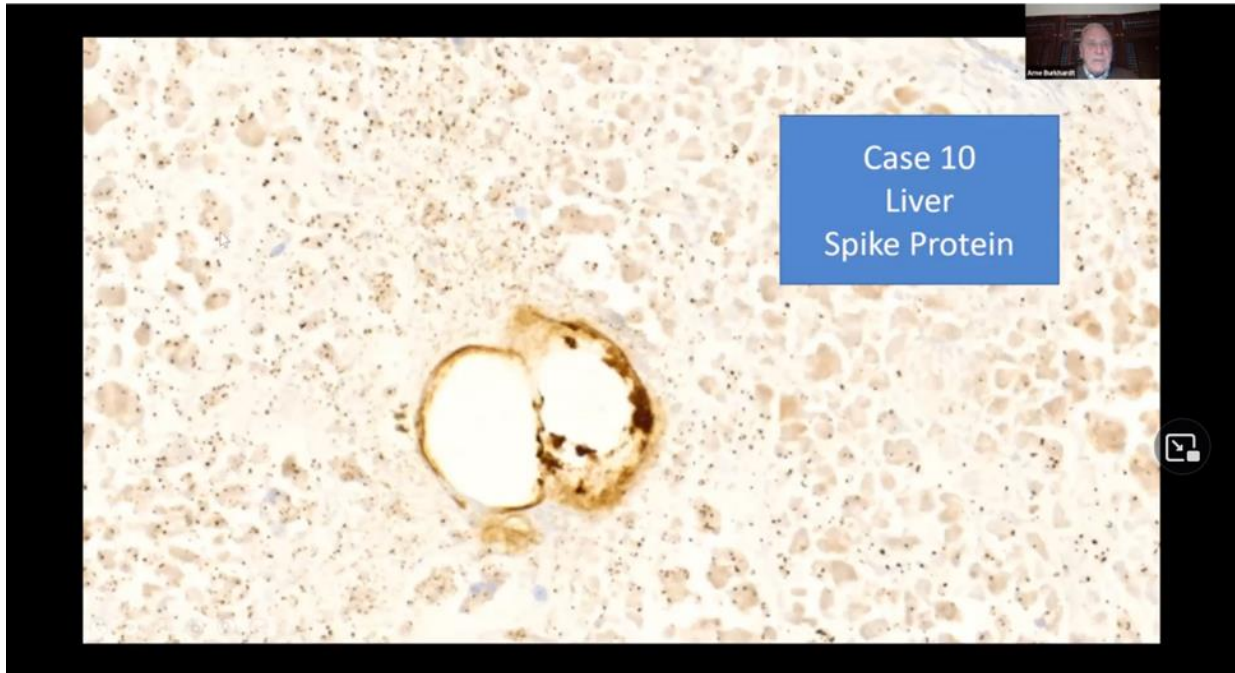

We first overlooked; but the more we looked, the more we found it. And this is one phenomenon that is known as **onionskin arteritis of the spleen**, which is **seen in some autoimmune diseases like lupus erythematosus**. And, in the course of these arteriolitis, we saw **focal destruction of follicular arteries in the spleen** and **products of the lymphatic follicles**.

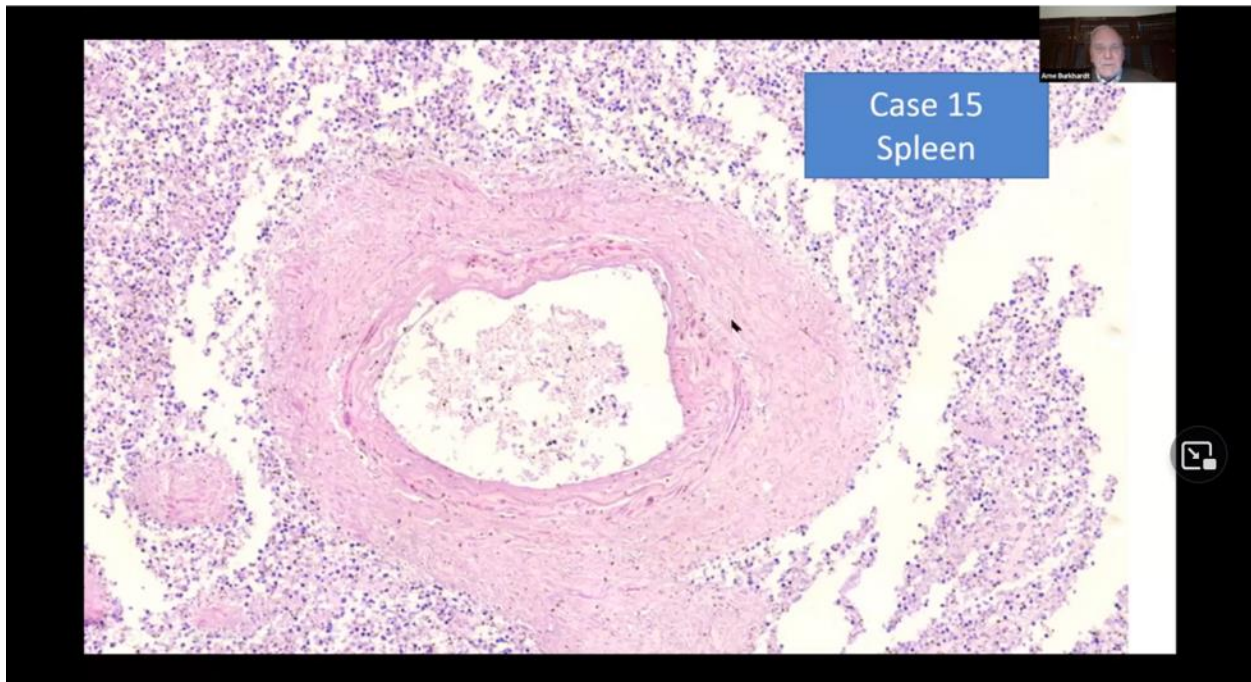
Now, first of all, this picture is an overview of two organs in one paraffin dock. You can see here the liver and here the spleen. And so, both organs have had the same preparation, the same fixation and everything.

So, you can see easily that the **liver is practically non-reactive**. You can see **some small vessels in the endothelium are positive, but the liver itself is negative**.

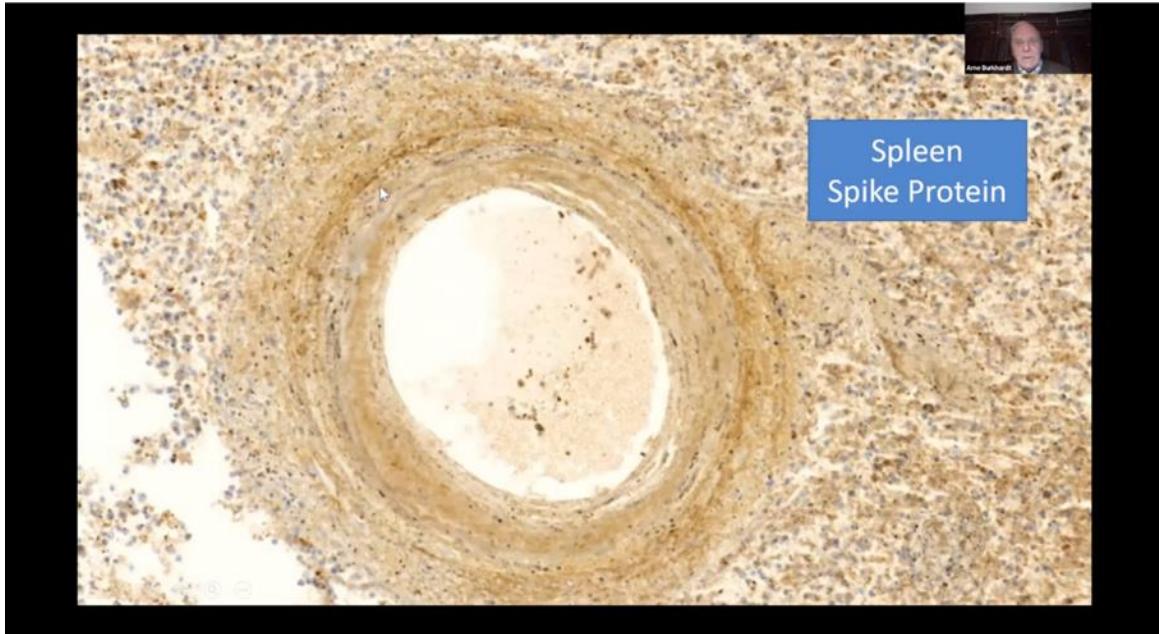And then, in contradiction, the spleen has a very pronounced mark around the vessels and small arterioles.



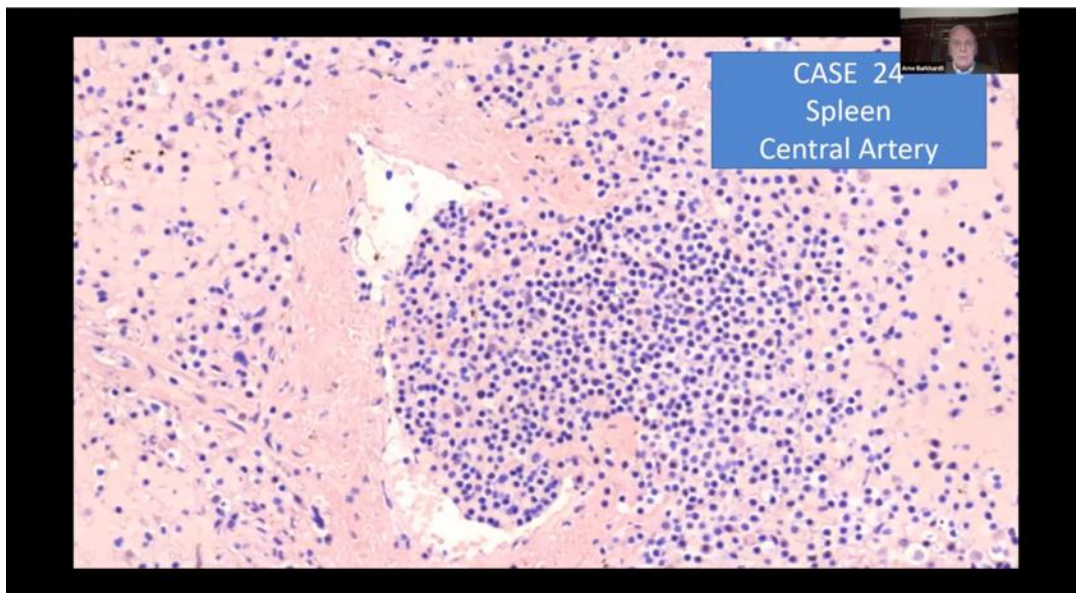
This is a liver now; and you can see the liver cells itself are negative, but the small vessels, the capillaries, have a strong, positive reaction of the endothelium (*indicative of Spike protein*).



Spleen showing the “onionskin” phenomena that is seen in some autoimmune diseases. Concentric layering is seen in the thickened arterial wall. Surrounding the artery, hypercellularity is visible with intense nuclear material reaction (blue dots).



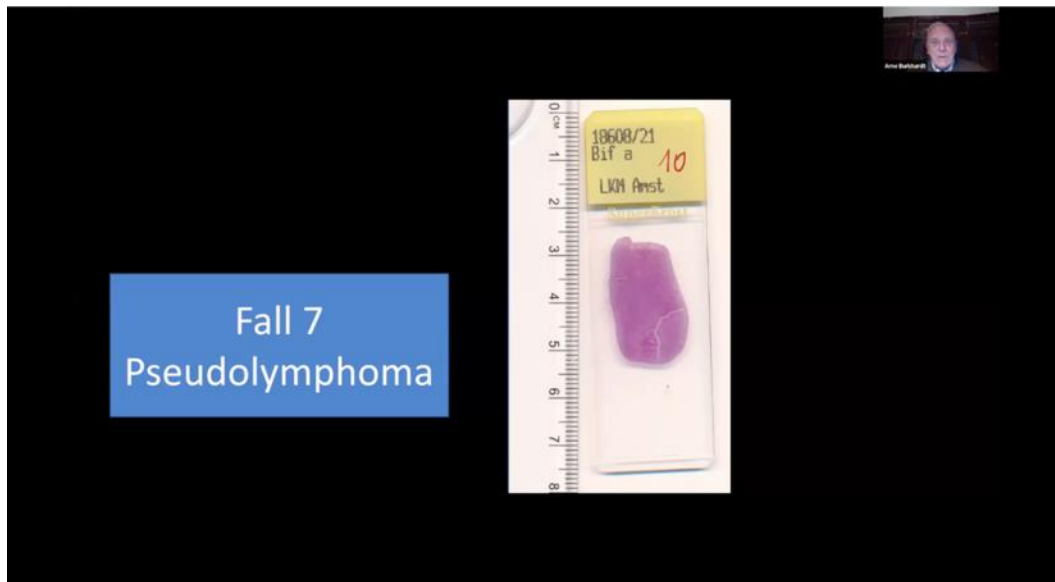
And this is this reaction that is called the onionskin phenomenon, which is seen in some autoimmune diseases. You can see the wall of the artery is split up in, in a way. And also, here we can show, as we saw on the overview that **there's a strong reaction for the Spike protein.**



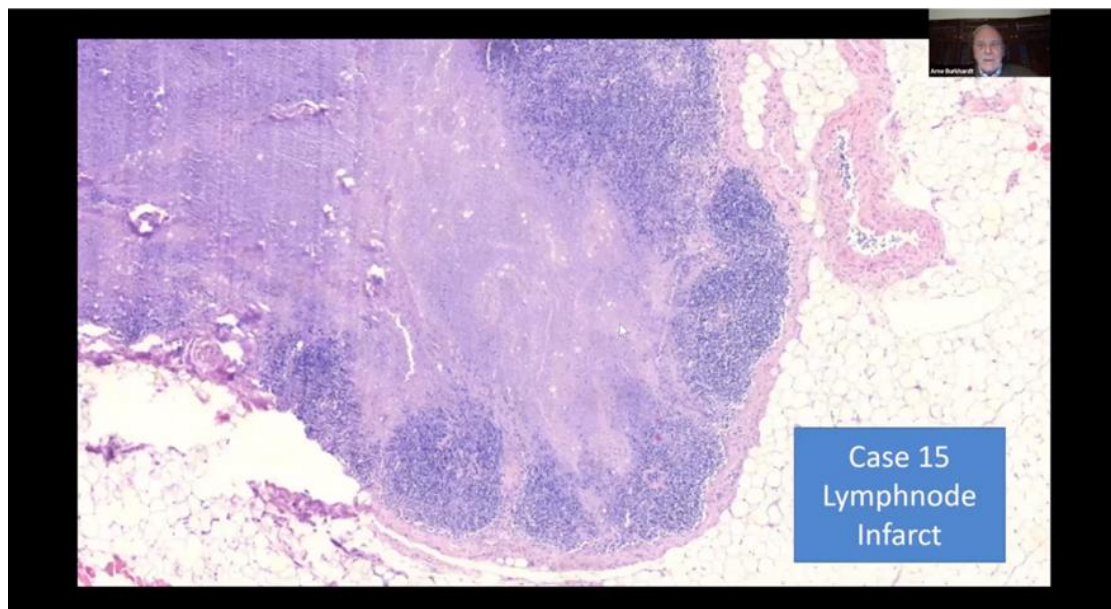
And **this is a phenomenon that none of the pathologists that I work together have ever seen.** This is a **small follicular artery in the spleen**; and you can see the **wall has a focal defect, and the lymphatic tissue is protruding into the vessel.**

Lymph Nodes, Pseudolymphoma, Neoplasia

So, it also changes in the lymph nodes. Densely packed with, possibly, **atypical lymphocytes that are locally invasive suggestive of neoplasia?**



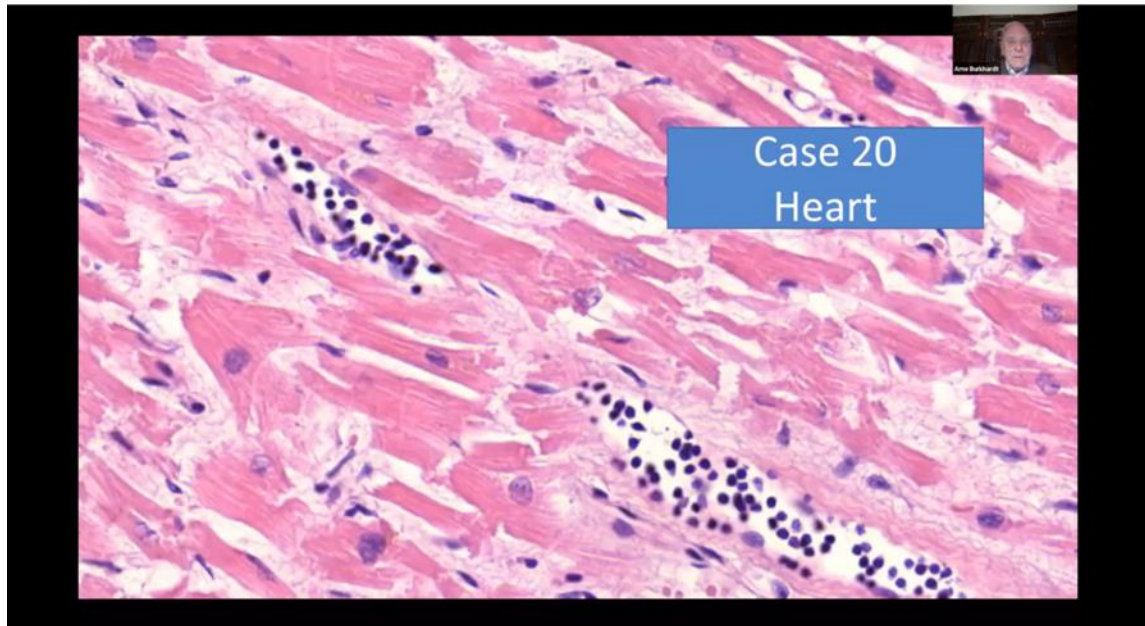
We have seen a case of a pseudolymphoma, as I can show you here. It's at least three centimeters large.



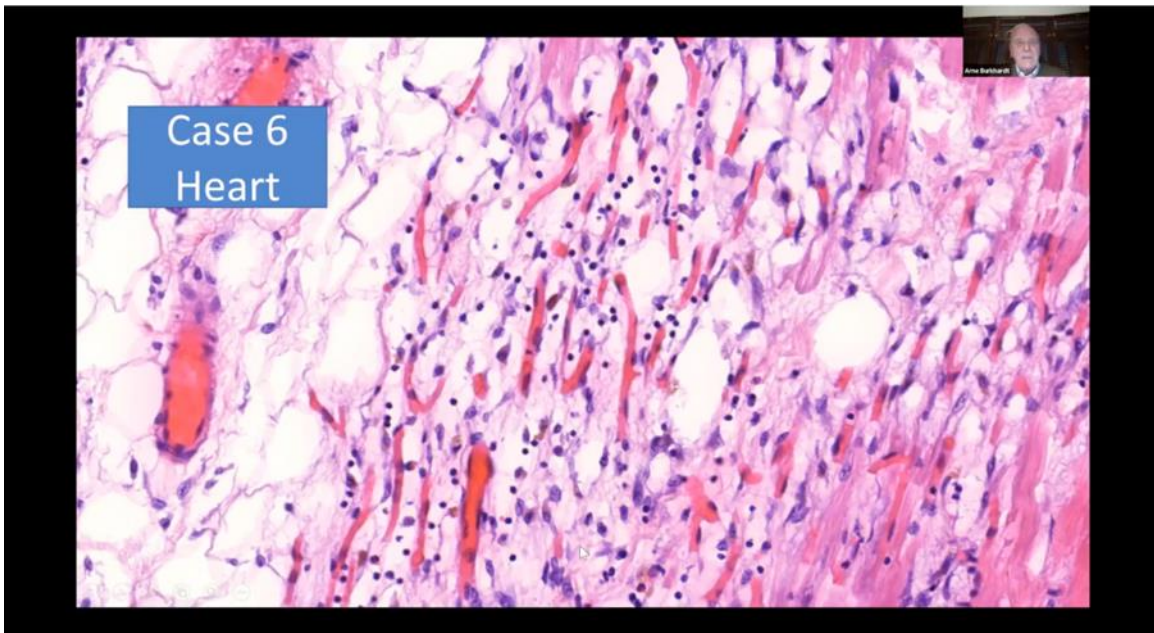
And then, in another case, we saw a focal central infarct of the lymph nodes. Infarction is suggestive of neoplasia, as cellular proliferation is so aggressive that it outstrips the local blood flow leading to infarction.

Heart

Now the **myocarditis** is now, I think, **it's internationally known that it is a side effect of vaccination.**

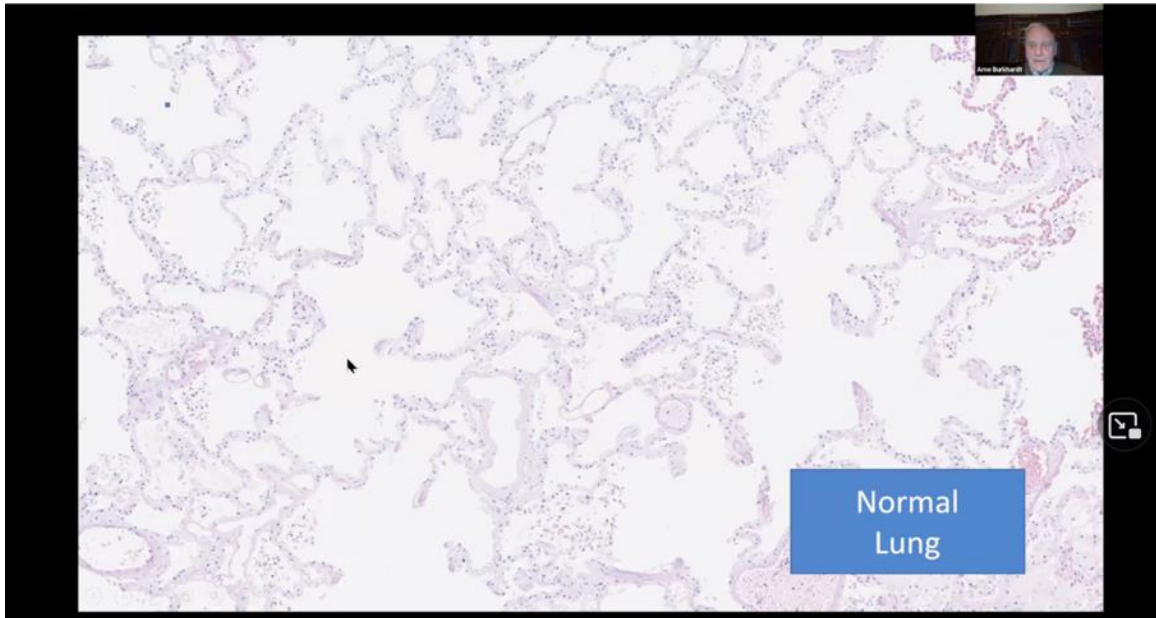

And you can see that, in our cases, we saw these **lymphocytes marching up in the small vessels here. You can see the intact muscular fibers.**

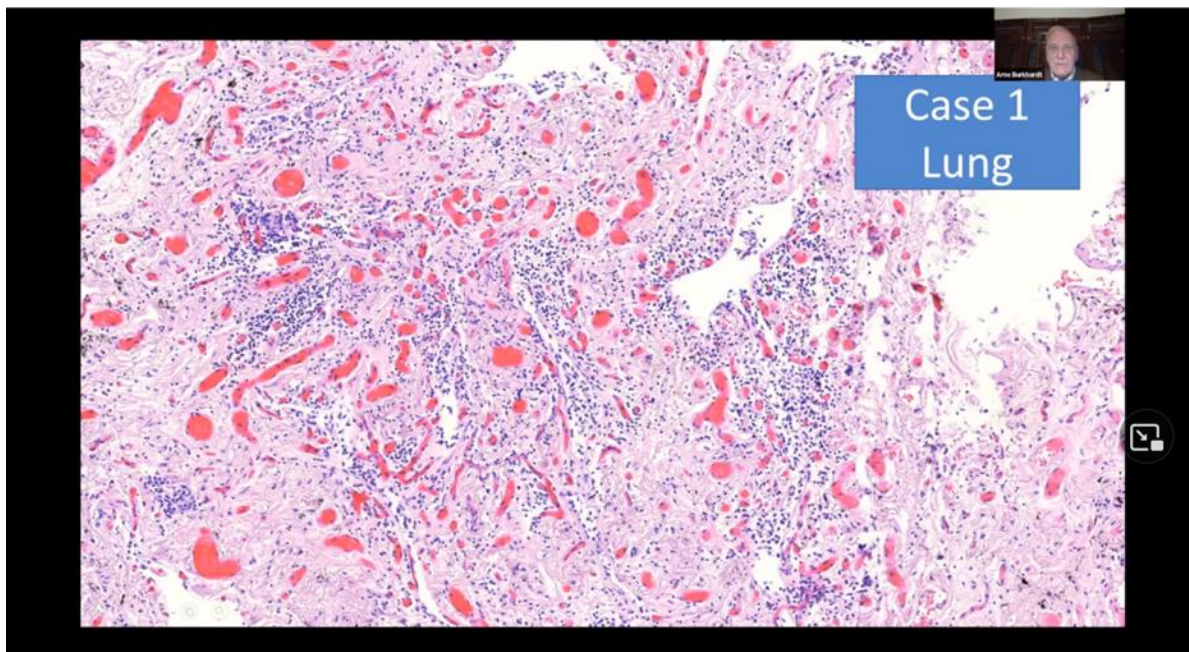


And, in this case, you can see that **they (cardiac muscle fibers) are destroyed by the lymphocytes that are infiltrating** in contradiction to true infarct of the cardiac muscles. Do not see granulocytes (*granulocytes are white blood cells also known as polymorphonuclear leucocytes that predominate in cases of non-vaccine-related myocardial infarction*) in these areas. Only very few when some macrophages, of course.

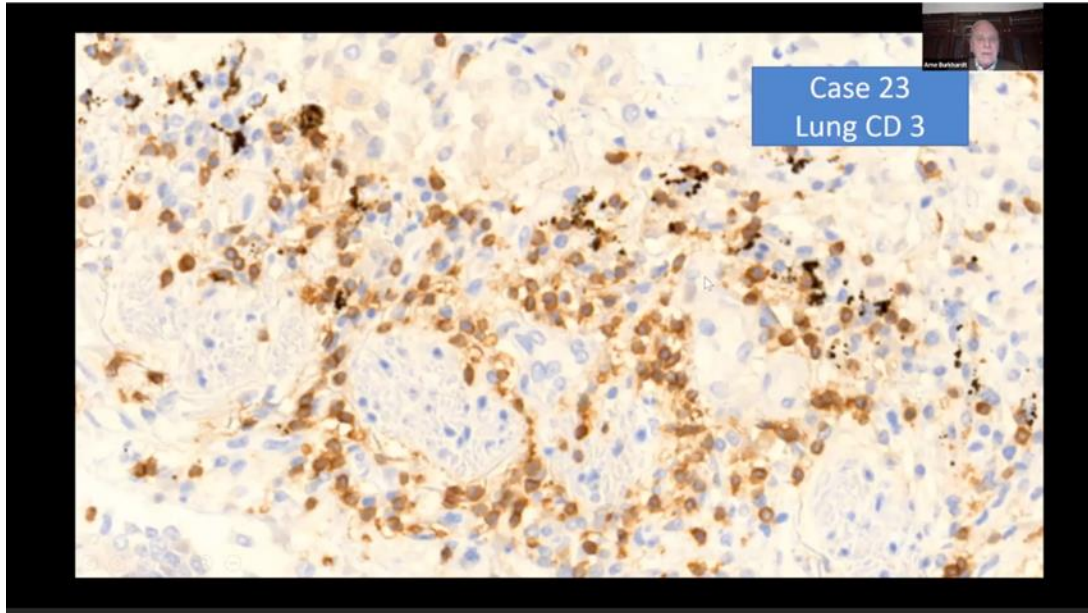
Lung



So, we come to the lung here. You see a normal lung. You can see here all the white areas of the lung alveoli.



And what we found are **very pronounced changes** in which you might call a **lymphocytic alveolitis, lymphocytic interstitial pneumonia**. And you can see that only **very few areas where there are still alveoli**.



The **infiltration is mostly T lymphocytes, CD3+**. (*T Helper? T Cytotoxic? or new Species: T Neoplastic Lymphocyte?*) Note the high concentration of Spike protein represented by rust-color stain.

Brain

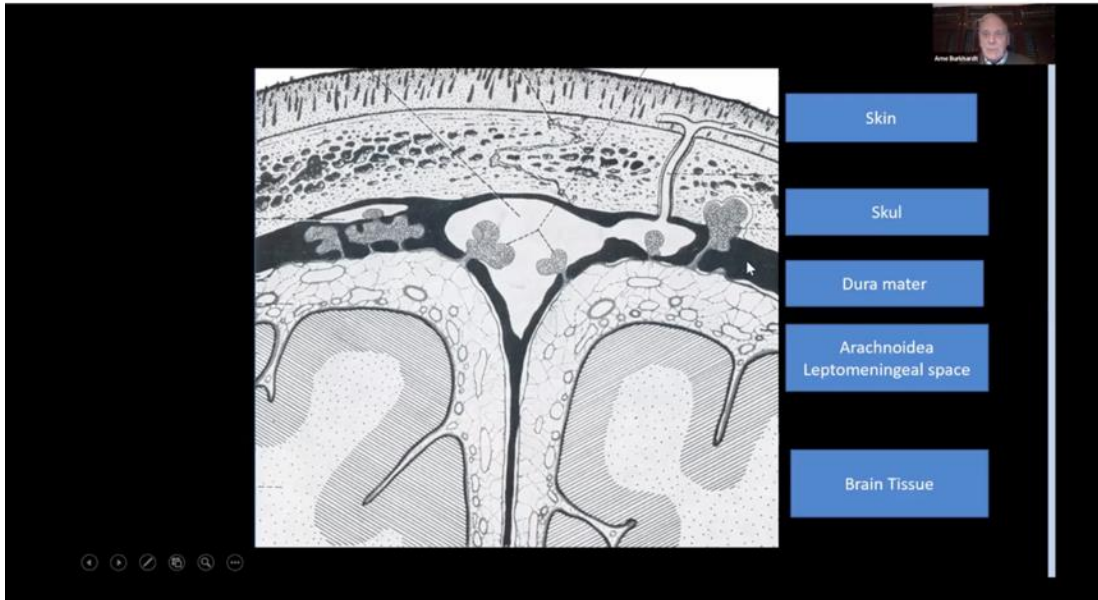
Very important are the changes that we found in the brain.

Main Pathological Findings

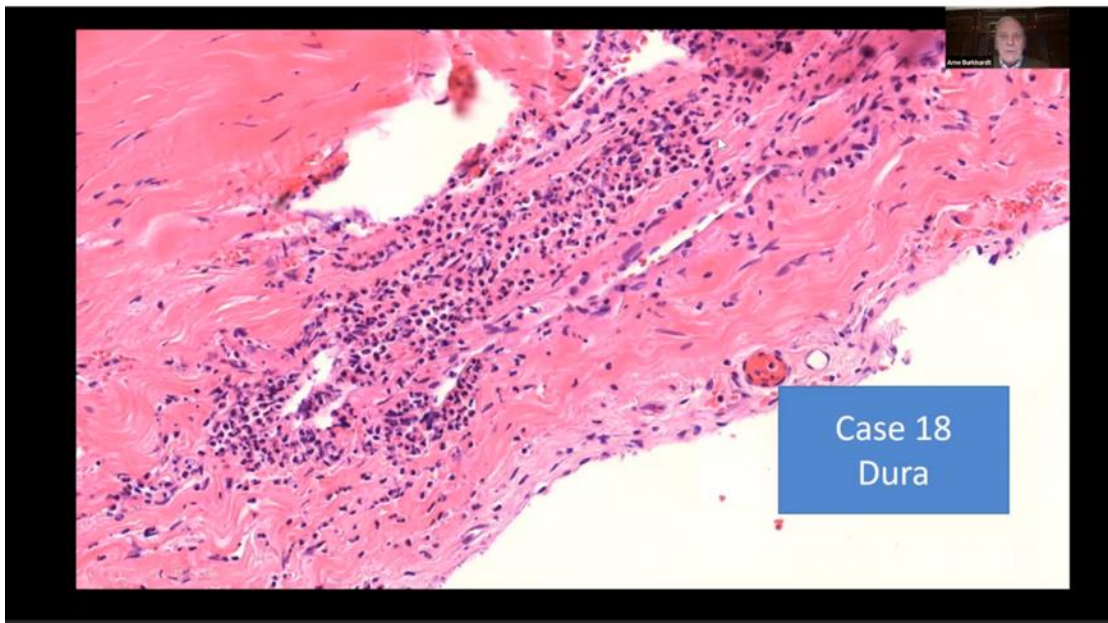
Brain

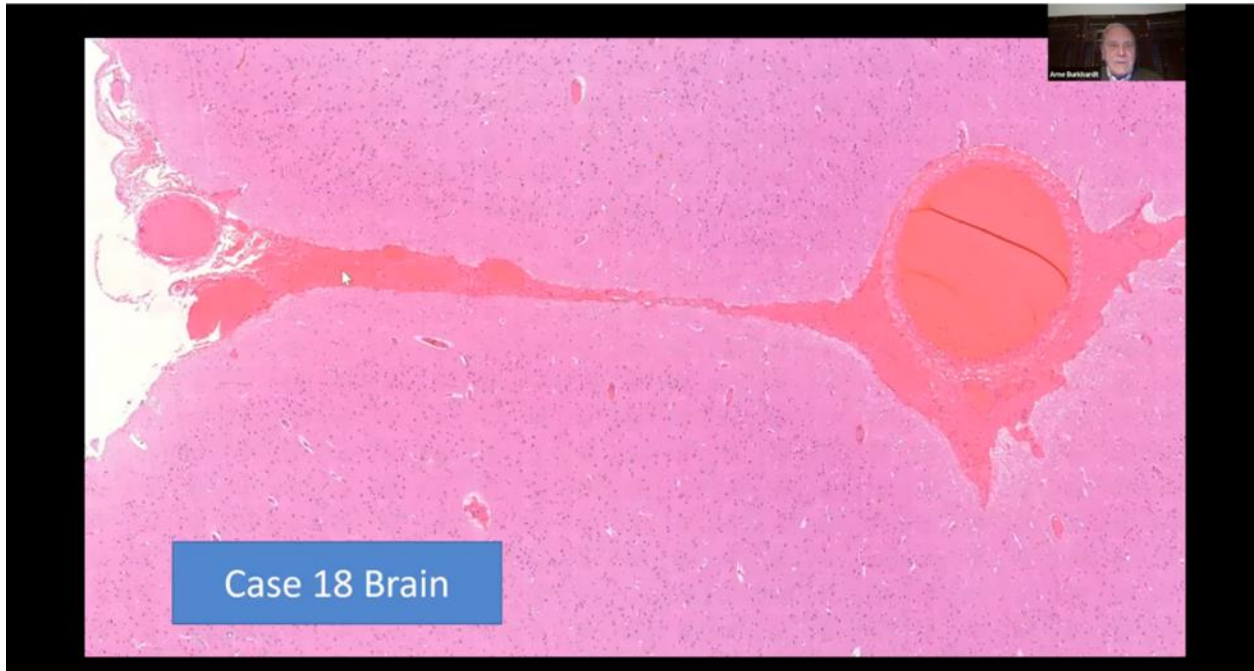
- Transfection-associated Encephalitis
- Lymphocytic Infiltration and focal destruction of intracerebral and arachnoidal Bloodvessels
- Subarachnoidal Haemorrhage without Aneurysma
- Focal lymphocytic Infiltration of the Dura mater
- Necrosis of the Hypophysis

We found a **transfection-associated encephalitis**, then **lymphocytic infiltration**, and focal **destruction of intracerebral and arachnoidal blood vessels**, subarachnoidal hemorrhage, without an aneurysm, in young people, focal **lymphocytic infiltration** is also **in the Dura mater**. In one case, **partial necrosis of the hypophysis** (*pituitary gland*).

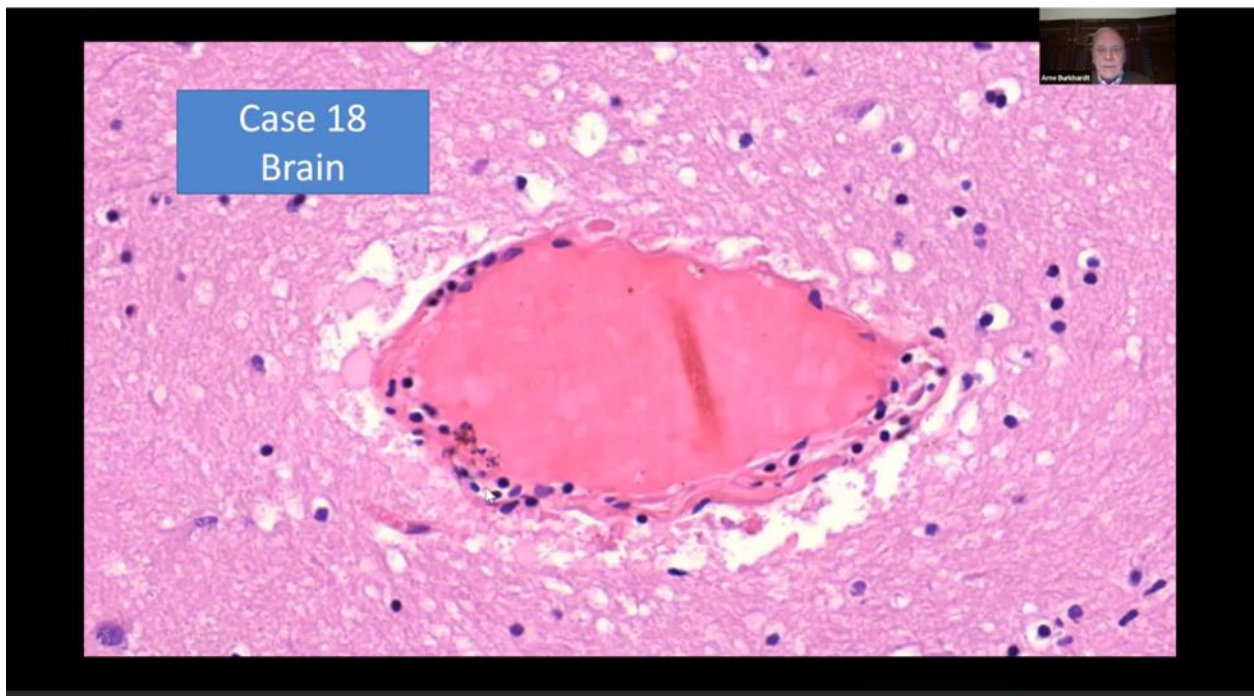


Now this, just for those that are not familiar, this is Dura mater. And here we found infiltration by lymphocytes. This is the **arachnoidea** where we found **perivascular inflammation**, and we **also** found it in the **brain**. This is Dura mater; you can see this focal infiltration by lymphocytes.

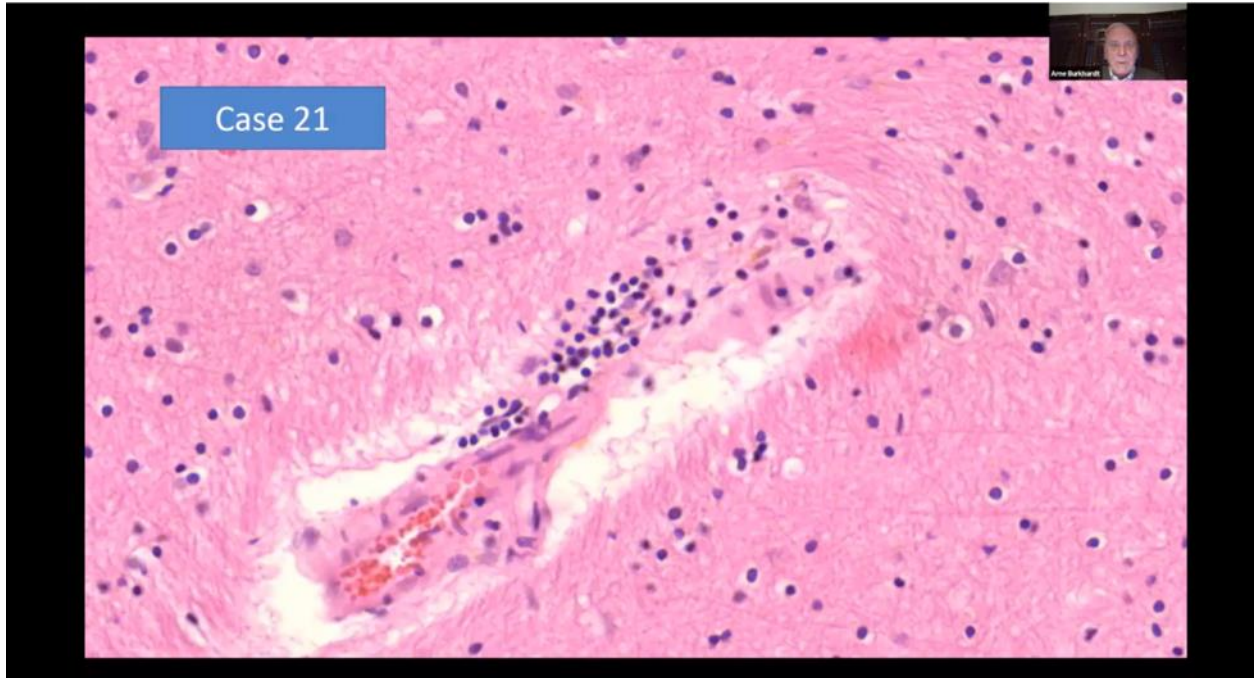




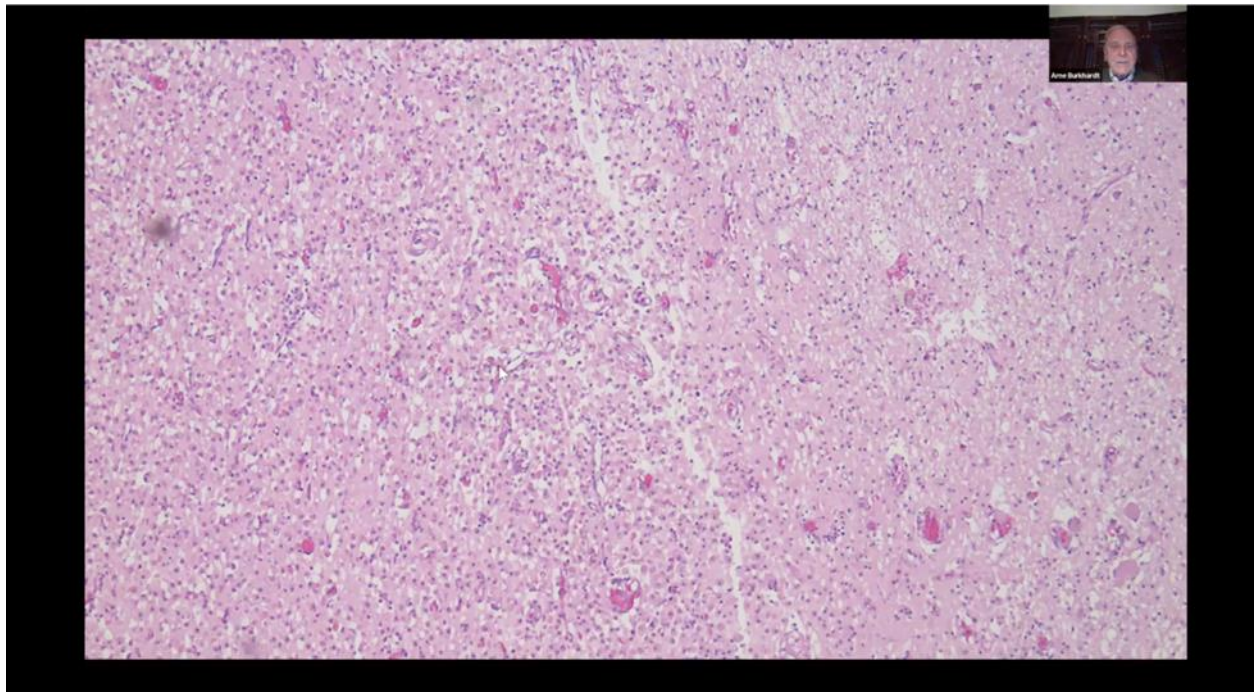
This young 26-year-old died of hemorrhage (*arrow at 9 o'clock*). No aneurysm.



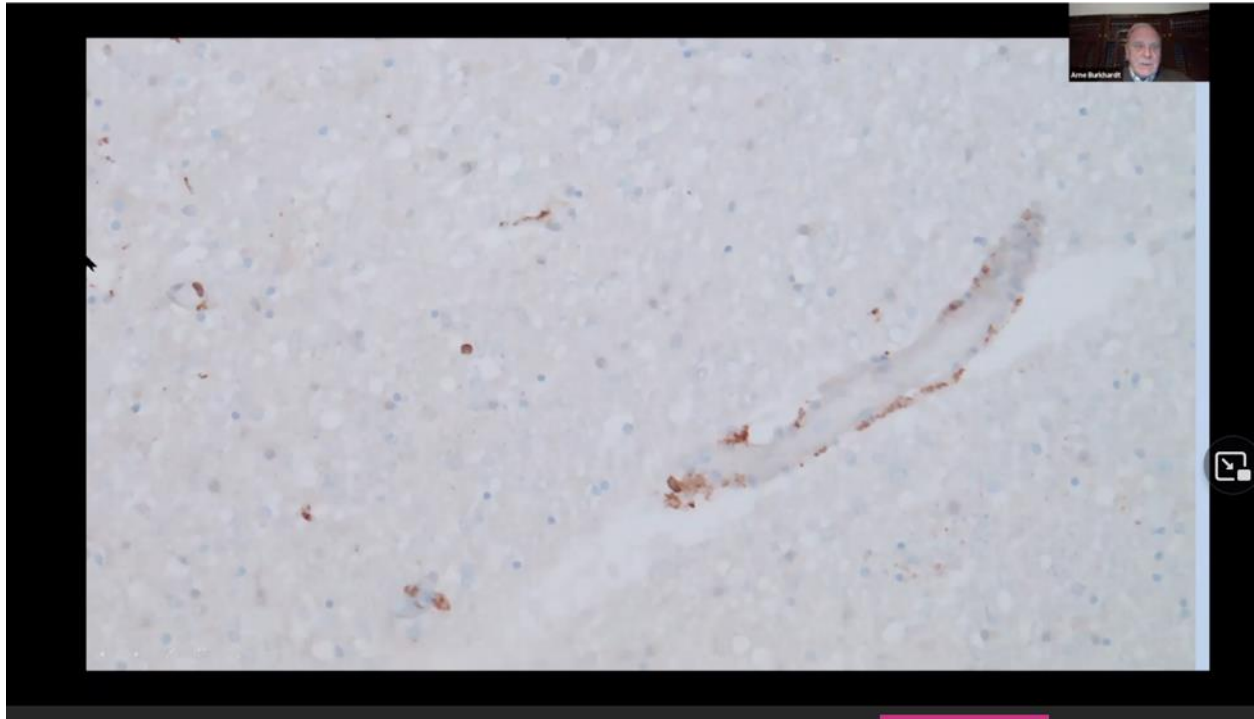
You can see that the **vessels in the brain** and in the [inaudible] have a **focal lymphocytic infiltration, and, probably that caused a rupture**. Also,



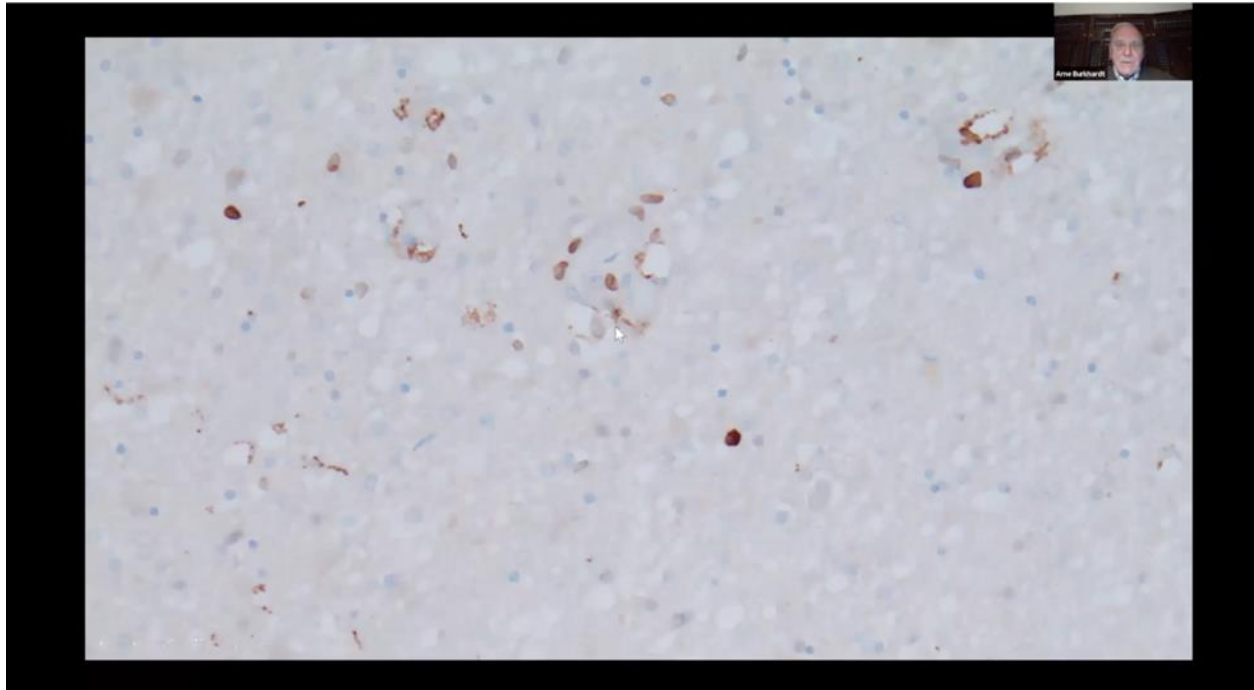
infiltration by lymphocytes.



And this is a case of encephalitis which we observed.

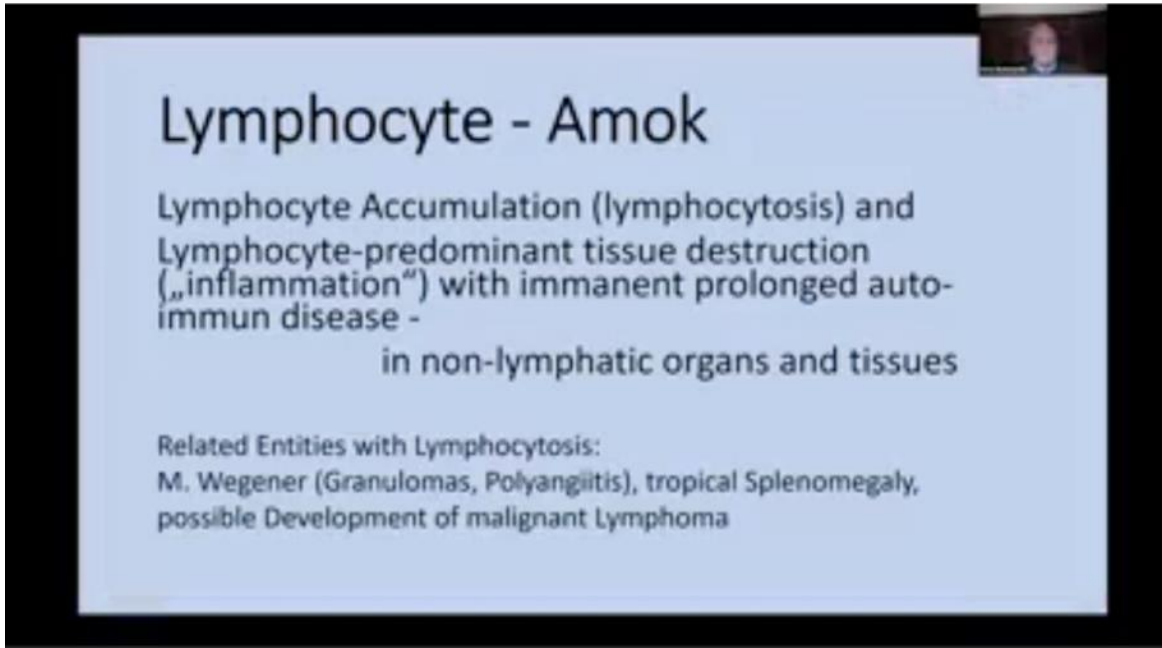


And in this case, we could demonstrate a **Spike protein**, again, **in the smaller vessels**. And here, a small artery; here, very pronounced, positive reaction.



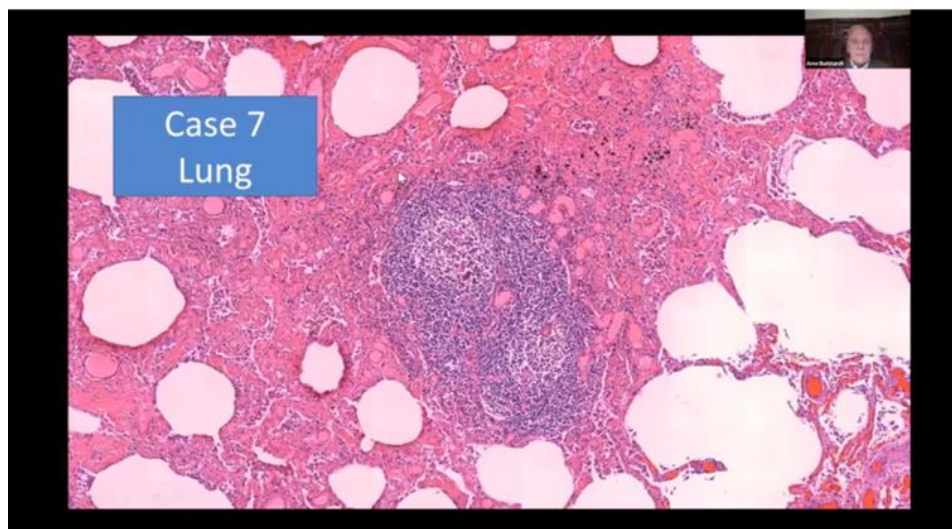
Another area where you can see this definitely and very clear positive cells. It's mostly in the small vessels, but **also in some neural cells**.

Lymphocyte “Bee-Hiving”



And now in a phenomenon that we call the **Lymphocyte – Amok, which is a lymphocyte accumulation and lymphocyte predominant tissue destruction outside of the myocardium and the lung** where I’ve already demonstrated this.

It’s definitely the danger of a prolonged autoimmune disease. And this we found in non-lymphatic organs and tissues. There are some autoimmune diseases which are related to this phenomenon.



And this is in the lung. In the lung, sometimes you find small lymphocytic elements; but I have never seen before a quasi-lymph node with reaction centers and activation.

Organ	Cases
Thyroid Gland	2 Cases (5,13)
Salivary Glands	2 Cases (7, 15)
Aorta, larger Vessels	7 Cases (3,6,7,9,13,19,20)
Skin	2 Cases (4,20)
Liver /NASH	1 Case (8)
Kidney	3 Cases (12,14,19)
Lymphocytic Pyelonephritis/Nephritis/Ureteritis	1 Case (19)
Testis	1 Case (10)
Dura	1 Case (19)

And this is the frequency that we found of these lymphocytic infiltrations, the thyroid glands, the salivary glands. And by the way, of course, we found this in two cases, but we only had these organ specimens in two cases. So, it was found in 100% of the cases that we examined.

So, in the aorta, I showed you before, skin liver, kidney, lymphocytic pyelonephritis, nephritis, in the testis, in one case, and in the Dura, I showed you this phenomenon.

Fourteen cases with lymphocytic infiltration outside of the lungs:

- Seven cases with aorta and large vessels;
- Three cases with kidney;
- Two cases each with salivary glands, skin, and thyroid;
- One case each with Dura, pyelonephritic/urethritis, liver/NASH, testis;

One patient (#19) had five sites of lymphocytic infiltration: aorta/vessels, kidney, skin, Dura, lymphocytic pyelonephritis/Urethritis

So, these are the organ changes.

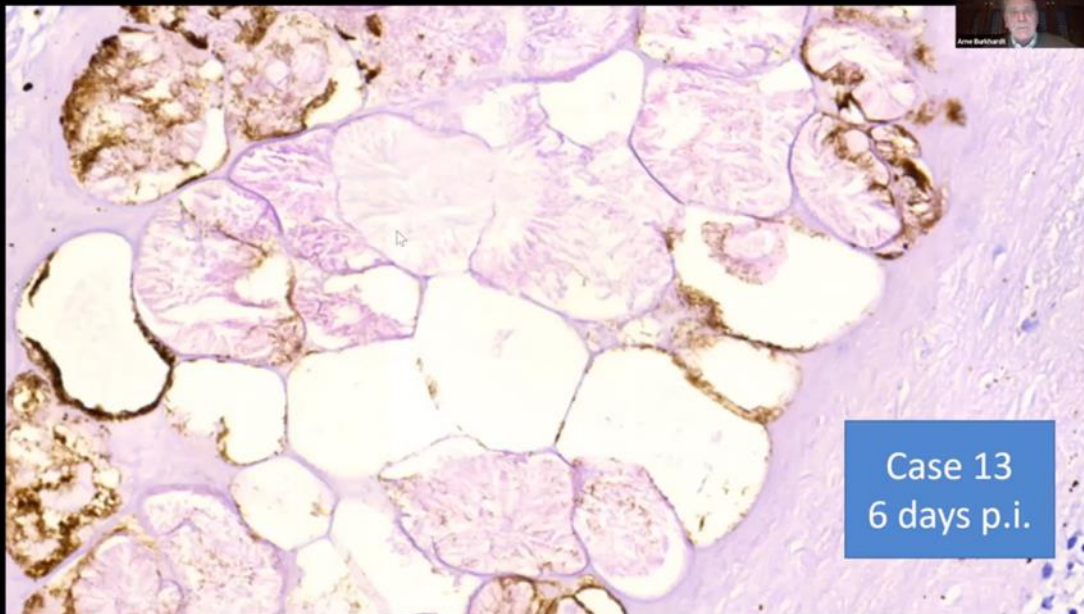
Unidentified Foreign Material in Vessels

And, just as the last lesions that I would like to show you, is **unidentified foreign material in the vessels, especially in the spleen vessels.**



Unidentified foreign Material in Vessels

- 5 Cases



Case 13
6 days p.i.

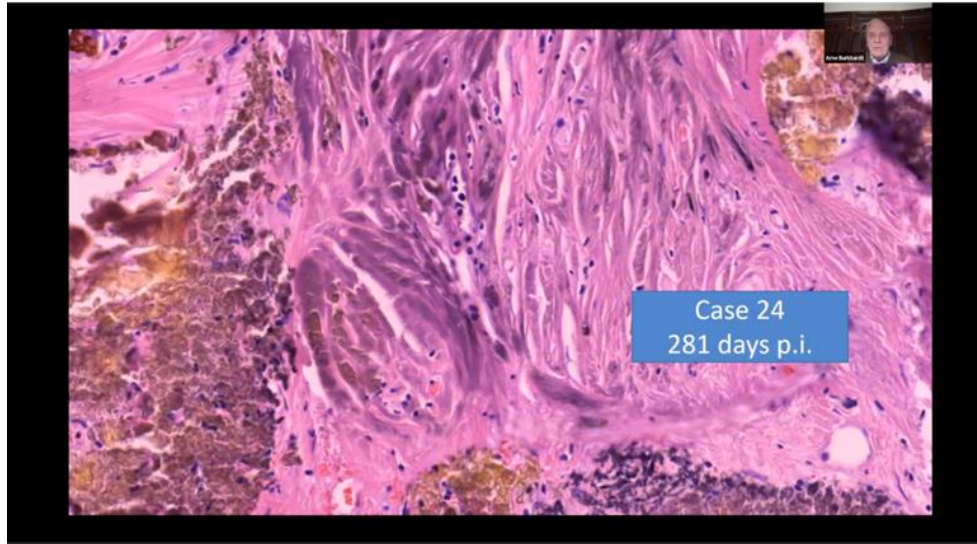
And this is something that we could not identify. (*White arrow at 9 o'clock.*)

No pathologists that have looked at it know what it is.

First, we saw these cells, but they have an inner structure like [inaudible]; and then we thought it might have been a contrast material, but this patient died at home and was not in the hospital for a long time.

And this was one case in the spleen, and this is another after some longer period of time.

So, **our theory is that these are the nanolipid particles, which when they come into the body and are warmed up, which coalesce and form larger particles that might, at one point, stick in the system, in the vessel system.** And this was one case in the spleen,



and this is another. *The last* one was only a few days, and this is after some longer period of time. I might add that this is a coincidental finding because this was not macroscopically seen, but we had it by coincidence in our sections.

Case Report

I will show you a case report over natural death uncovered as caused by vaccination-induced vasculitis of the coronary artery.

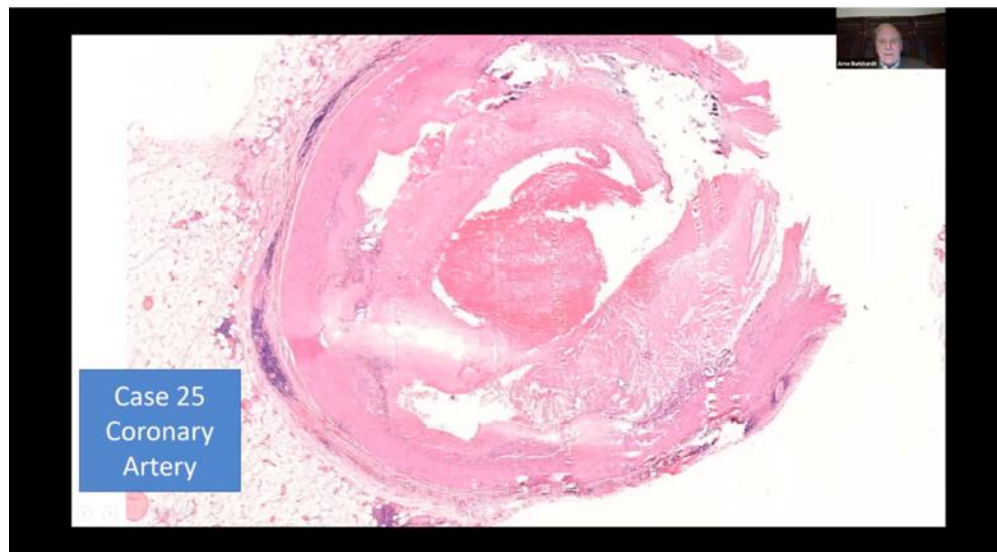
A slide titled "Case Report (Case 25)" with a light blue background. The text on the slide reads: "„Natural“ Death uncovered as caused by Vaccination-induced Vasculitis of Coronary Artery". Below this, there is a bulleted list: "• 54 Year old Man, 1. Vaccination AstraZeneca", "• 2. Vaccination Comirnaty", and "• Death 123 days after second Vaccination presumably by Myocardial Infarct". Underneath the list, the heading "Autopsy with Histology" is followed by the text: "Texture Disturbance and marked Perivasculitis of the Coronary Artery with Thrombus-Formation", "Preexisting Arteriosclerosis", and "Myocardial Infarct and Lymphocytic Myocarditis". There is a small video feed icon in the top right corner of the slide.

It was a 50-year-old man, two vaccinations, and he died 123 days after the second vaccination.

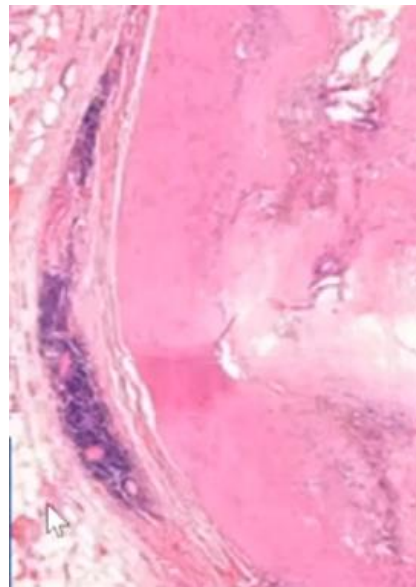
And there was no doubt this was myocardial infarct. The primary autopsy was *contested*.

They saw a discoloration of the cardiac muscle and said, “Well, yes, he died of a myocardial infarct;” but then we did histology of the coronary artery, and we found these changes.

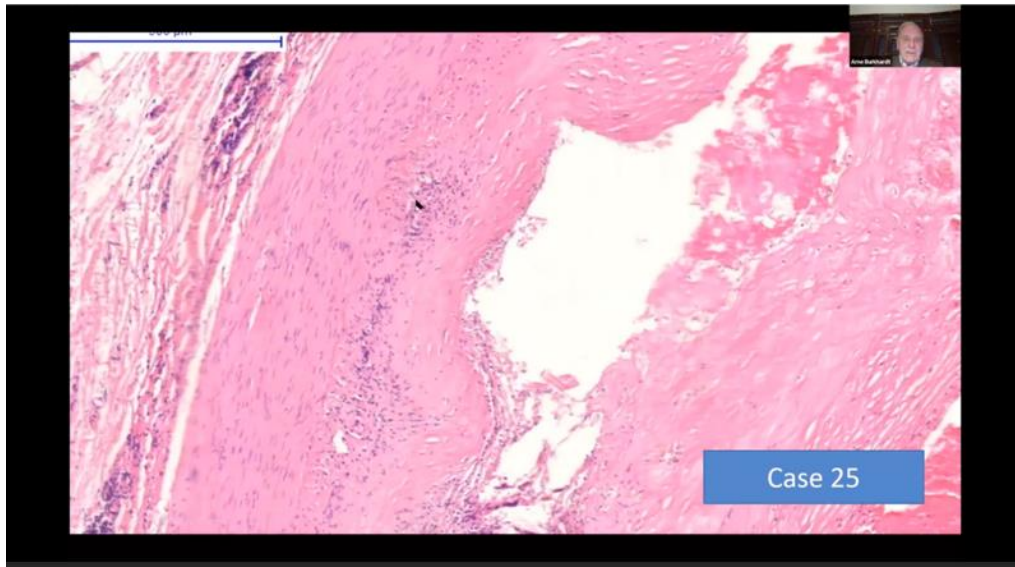And, in addition, in the muscle we found the **myocarditis**, as we found typically in the other cases, as I have shown.



Now this is the coronary artery and, yes, you see it's clearly there; *there is* thrombus formation inside. And yes, there are arteriosclerotic changes.

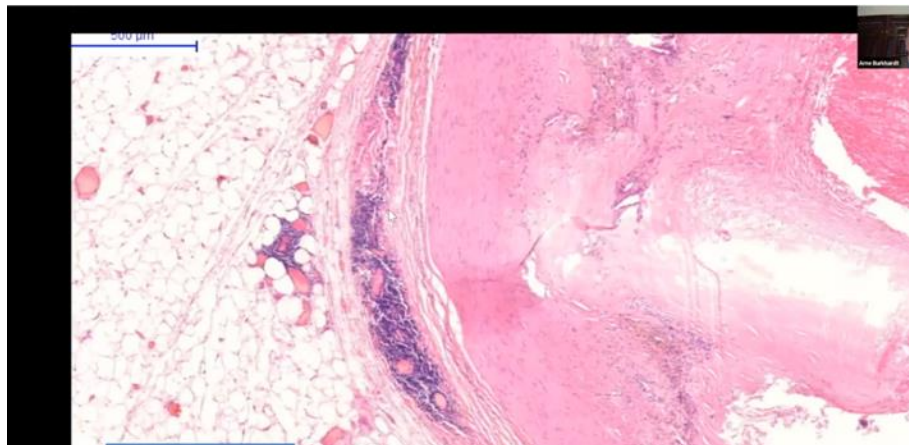


But look at these areas and here around the vessel. There's definitely inflammatory reaction. (*At 8 to 10 o'clock outside the pink thrombus in the coronary artery to the right of the clue staining tissue.*)



And you can see this disturbance of texture of the smooth muscle and the myofibroblasts here, and you can see also some discrete lymphocytic infiltration.

And then, around the vessel, there's this dense lymphocytic infiltration.

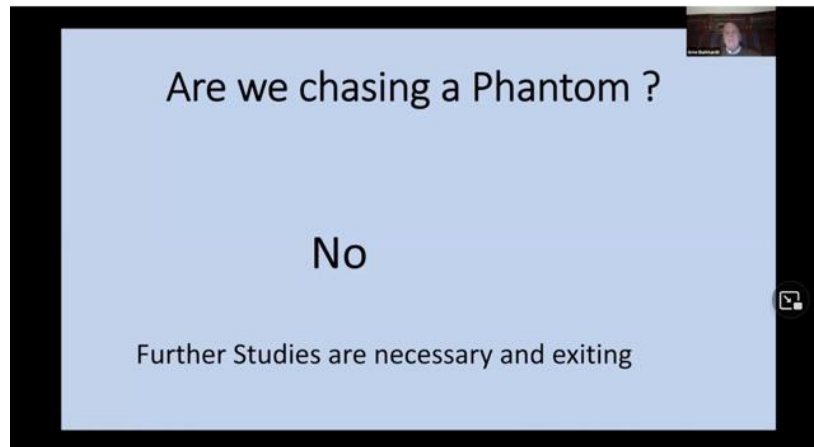


So, we concluded that the vessel, the coronary artery, had an inflammation induced by the vaccination, by the Spike protein.

And the thrombus was built on the ground of these inflammatory changes and led to the infarct, which definitely was present.

But also, the fact that there was a concomitant, myocarditis, very strong evidence that this secondary, because of the vaccination.

And we spent many, many hours looking at all these slides.



And for a long time, we were thinking, "Well, we are chasing a phantom;" and we looked at each other and ask each other, "Do you see this? Do you see this? Is this real?"

And we are now at a point, and especially after we could prove the presence of Spike protein for months after vaccination, we are come to the conclusion, no, we are not chasing a phantom.

Further studies are necessary, and I think it's a very exciting field that we are coming to; but also a very depressing and very scary phenomenon.

Thank you.

Dr. Mark Trozzi:

So, I'm going to pick two questions. One is very sweet, and it's an anonymous attendee who says, "Professor Burkhart, do I understand that you came out of retirement to help us, the people of the world in need?"

"Well, actually, I was just retiring a few months before I started to study. I gave back my license for the health insurance in April last year. And, in May, I was contacted, and they asked me if I would do this study. And I, by the way, I also have some consulting contracts with some other laboratories.

So, I'm not retired in the way that I am not active anymore, but I'm retired in the sense that I am not responsible to anybody, and that **I cannot be thrown out of my job.** I'm independent."

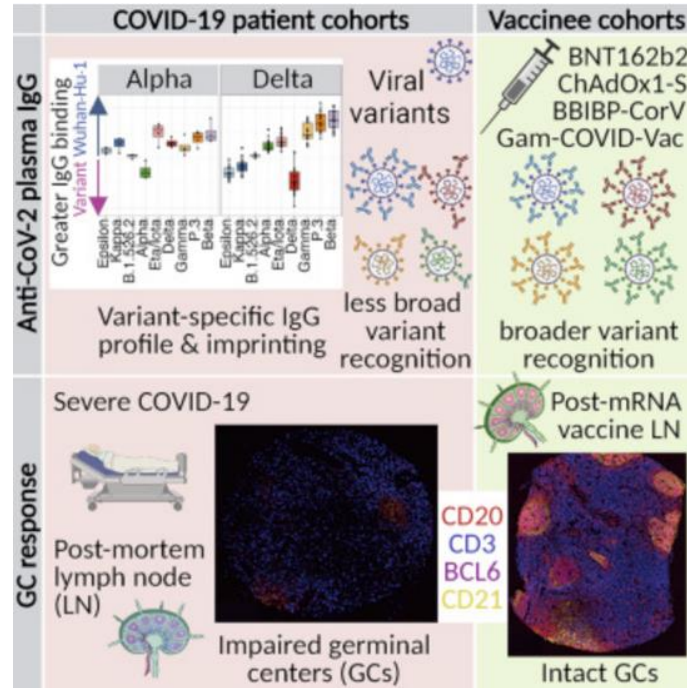
An underlying theme of the histopathology of LNP/mRNA harms is involvement of vascular structures, arteries and veins. Table 1 identifies vascular involvement in the 20 cases.

**Table 1: Histopathology from LNP/mRNA Involving the Vascular System
(Burkhardt Series)**

	Vasculitis 11 Cases	Vasculitis/Perivasculitis 10 Cases	Vasculitis/Perivasculitis 6 Cases	2 Cases
Patient	Endovasculitis: Endothelial swelling, Desquamation, Focal Lymphocytic Infiltration, Main Localization: Heart and lung	Lymphocytic Infiltration of Vasa Vasorum,	Focal Media-Necrosis and Inflammatory Reaction	with Thrombosis
1	X	X		
2	X	X		
3			X	
4	X	X		
5	X	X		
6			X	
7	X	X	X	
8	X	X		
9	X	X		
10				
11				
12				
13		X		
14	X		X	
15				
16				
17				
18	X	X		
19			X	
20	X	X	X	
	11	10	6	2

Lymphocytes of various types have been identified in proximity of cellular, tissue and organ damage and may come from activated germinal centers as identified by the Boyd group at Stanford, <https://doi.org/10.1016/j.cell.2022.01.018>.

Table 2: Possible Origin of “Activated” Lymphocytes



This study found that Covid-19 impairs the lymph node germinal centers but transfection with Spike based therapeutics was found to stimulate the germinal centers:

“The biodistribution, quantity, and persistence of vaccine mRNA and spike antigen after vaccination and viral antigens after SARS-CoV-2 infection are incompletely understood but are likely to be major determinants of immune responses.”

Presumably this also means that the activated lymphocytes produced by the ongoing activity of the transfected mRNA have not been studied as well including potential detrimental effects such as autoimmunity from protein mimicry and neoplasia from genome dysregulation.

“The observed extended presence of vaccine mRNA and spike protein in vaccinee LN GCs for up to 2 months after vaccination was in contrast to rare foci of viral spike protein in COVID-19 patient LNs.”

This is an important difference between Covid-19 and the Spike based therapeutic products and at least partially explains the long-time course of harms from the Spike producing products that range from 7 to 180 days in the Burkhardt series (average 45 days).

Table 3: Lymphocyte Associated Organ System Pathology from Spike Producing Therapeutics

	Lymphocytic Infiltration Active Cases	14 Cases							
Patient	Aorta and larger vessels	Kidney	Salivary Glands	Skin	Thyroid Gland	Dura	Lymphocytic Pylonephritis /Ureteritis	Liver/NASH	Testis
1									
2									
3	X								
4				X					
5					X				
6	X								
7	X		X						
8								X	
9	X								
10									X
11									
12		X							
13	X								
14		X			X				
15			X						
16									
17									
18									
19	X	X		X		X	X		
20	X								
	7	3	2	2	2	1	1	1	1

Consider the action of mRNA on the Lymphatic Germinal Centers with activation of lymphocytes while at the same time Spike related foreign proteins are being produced in distant tissues and organs.

Are these activated lymphocytes released from the Germinal Centers and hunt down and attack organs and tissues producing Spike proteins that are recognized as foreign? Do these activated lymphocytes produce tumors?

Table 4: Organ System Harms from Spike Producing Therapeutics

Burkhardt Series

Organs
Brain
Heart
Kidney
Liver
Lungs
Lymph Node
Salivary Gland
Skin
Spleen
Testis
Thyroid
Vascular

As cases accrue, the number of organs is expected to increase.

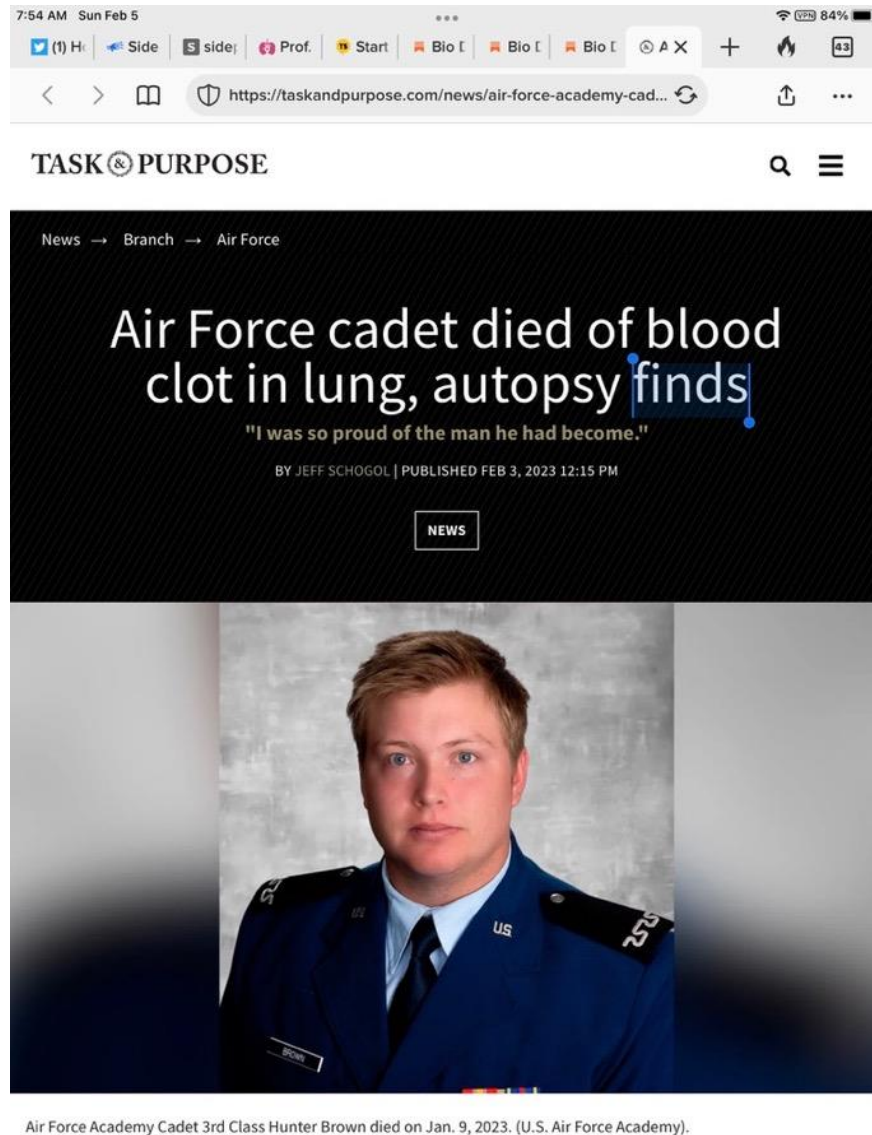
Table 5: Histopathology: Mechanisms of Injury

Histology	Definition
Apoptosis	Cell Death
Coagulopathy	Clotting
Infarction	Sudden Loss of Blood Supply
Infiltration	Abnormal Accumulation
Inflammation	Complex Chemical and Cellular Cascade that clears debris, microbes and begins Repair
Lysis	Dissolution
Necrosis	Death
Neoplasia	Pre Cancer or Cancer

Autopsy, Histopathology and Determination of Cause of Death

Case Report:

Hunter Brown, Age 21



The image is a screenshot of a mobile browser displaying a news article. The browser's address bar shows the URL: <https://taskandpurpose.com/news/air-force-academy-cad...>. The article's title is "Air Force cadet died of blood clot in lung, autopsy finds". Below the title is a quote: "I was so proud of the man he had become." The author is listed as "BY JEFF SCHOGOL | PUBLISHED FEB 3, 2023 12:15 PM". A "NEWS" button is visible below the text. The main image is a portrait of a young man in a blue Air Force uniform. Below the image is a caption: "Air Force Academy Cadet 3rd Class Hunter Brown died on Jan. 9, 2023. (U.S. Air Force Academy)."

“I’m heartbroken that I’ll never see him on the football field again, graduate from the Academy, establish a career, get married, or have kids,” she wrote. “He was my joy and I loved being his mom. I was so proud of the man he had become. We are so thankful for all of the support and prayers we have received, they have definitely eased some of the pain. Please continue to pray for our family.”

Autopsy for Air Force football player Hunter Brown released



BRENT BRIGGEMAN brent.briggeman@gazette.com Feb 1, 2023 Updated Feb 1, 2023 View Comments



A coroner has determined that [Air Force Academy Cadet 3rd Class Hunter Brown](#) died of a blood clot in his lungs that was caused by an injury to his left foot that he sustained during football practice weeks earlier, according to a copy of Brown's autopsy report that was provided to Task & Purpose.

The final diagnosis also noted enlarged liver, heart and spleen for Brown, a Louisiana native who was 6-foot-3 and 292 pounds at the time of his death at the at the age of 21.

Cadet Brown had a fracture dislocation of the base of his second toe that was repaired surgically. Blood clots (superficial or deep venous thrombosis) following surgery for an injury of this type is exceedingly rare and when they occur, they seldom break free and travel to the lung (pulmonary embolus).

Selby, Rita MBBS, FRCPC, MSc^{*,†}; Geerts, William H. MD^{*}; Kreder, Hans J. MD, MSc[‡]; Crowther, Mark A. MD, MSc[§]; Kaus, Lisa^{*}; Sealey, Faith RN^{*}. A Double-Blind, Randomized Controlled Trial of the Prevention of Clinically Important Venous Thromboembolism After Isolated Lower Leg Fractures. *Journal of Orthopaedic Trauma* 29(5):p 224-230, May 2015. | DOI: 10.1097/BOT.0000000000000250

ORIGINAL ARTICLE

A Double-Blind, Randomized Controlled Trial of the Prevention of Clinically Important Venous Thromboembolism After Isolated Lower Leg Fractures

Selby, Rita MBBS, FRCPC, MSc^{*,†}; Geerts, William H. MD^{*}; Kreder, Hans J. MD, MSc[‡]; Crowther, Mark A. MD, MSc[§]; Kaus, Lisa^{*}; Sealey, Faith RN^{*}

[Author Information](#)

Journal of Orthopaedic Trauma 29(5):p 224-230, May 2015. | DOI: 10.1097/BOT.0000000000000250

The primary effectiveness outcome was clinically important venous thromboembolism (CIVTE), defined as the composite of symptomatic venous thromboembolism within 3 months after surgery and asymptomatic proximal deep vein thrombosis on DUS. The primary safety outcome was major bleeding.

*Two hundred fifty-eight patients (97%) were included in the primary outcome analysis for effectiveness (130: dalteparin; 128: placebo). **Incidence of CIVTE in the dalteparin and placebo groups was 1.5% and 2.3%, respectively (absolute risk reduction, 0.8%; 95% confidence interval, -2.0 to 3.0).***

There were no fatal pulmonary emboli or major bleeding.

Assuming Hunter Brown had an extremely unlikely fatal pulmonary embolus such an event is sudden and catastrophic with no time to develop associated pathology in the liver, heart and spleen.

Hunter Brown's medical event and the associated autopsy findings do have an excellent match with the pattern of organ damage from Spike producing therapeutic agents (SPTA). In a report of what the authors' believe was the first autopsy in a Spike producing therapeutic associated fatality nine different organs or tissues were damaged by the LNP/mRNA.

Contents lists available at ScienceDirect

International Journal of Infectious Diseases

ELSEVIER

journal homepage: www.elsevier.com/locate/ijid

INTERNATIONAL SOCIETY FOR INFECTIOUS DISEASES

Short Communication

First case of postmortem study in a patient vaccinated against SARS-CoV-2

Torsten Hansen^{a,*}, Ulf Titz^a, Nidhi Su Ann Kulamadayil-Heidenreich^b, Sabine Glombitza^c, Johannes Josef Tebbe^b, Christoph Röcken^d, Birte Schulz^a, Michael Weise^b, Ludwig Wilkens^c

^aInstitute of Pathology, University Hospital OWL of the University of Bielefeld, Campus Lippe, Detmold, Germany
^bDepartment of Internal Medicine, Gastroenterology and Infectious Medicine, University Hospital OWL of the University of Bielefeld, Campus Lippe, Detmold, Germany
^cInstitute of Pathology, KRH Hospital Nordstadt, Hannover, Germany
^dInstitute of Pathology of the University of Schleswig-Holstein, Campus Kiel, Germany

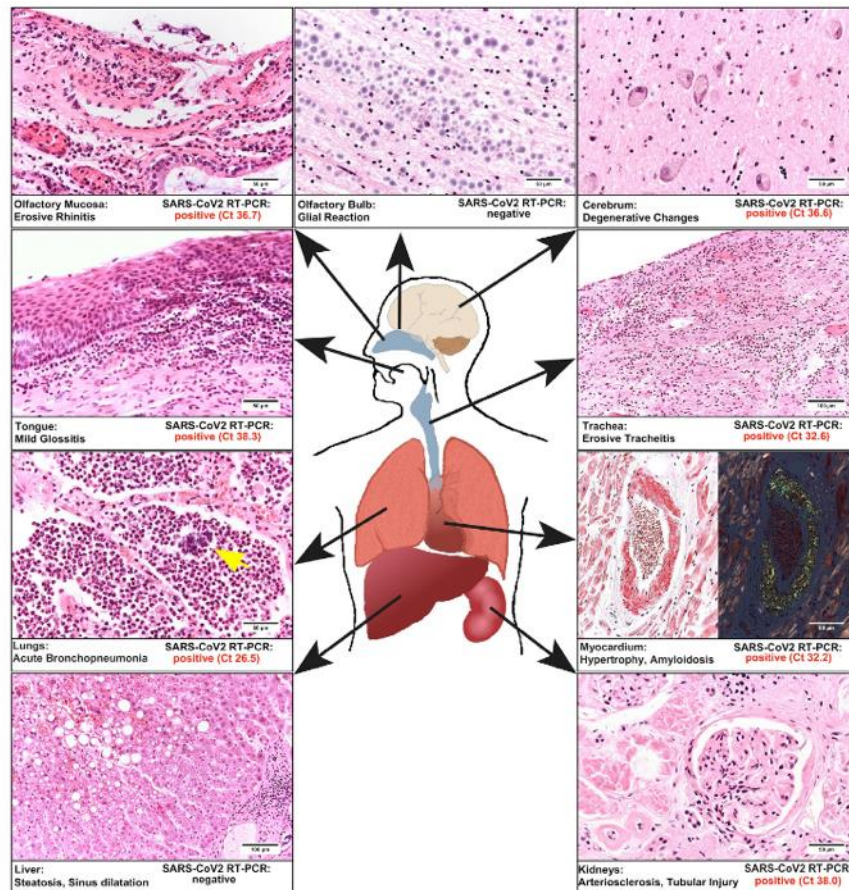


Figure 1. Synopsis of the relevant histological findings and the results of molecular mapping is presented. The histomorphology is obtained by standard hematoxylin and eosin reaction, except for the myocardium on the right side (Congo red staining). The magnification is shown by bars. Note that in the lungs, we also observed colonies of cocci (arrow) in granulocytic areas. In addition, the results of molecular mapping are given as evaluated cycle threshold values of the real-time polymerase chain reaction for SARS-CoV-2. Note that only in the olfactory bulb and the liver SARS-CoV-2 could not be detected.

Conclusions from Drs. Bhakdi and Burkhardt²:

- 1. Histopathologic analyses show clear evidence of vaccine-induced autoimmune-like pathology in multiple organs.**
- 2. That myriad adverse events deriving from such auto-attack processes must be expected to very frequently occur in all individuals, particularly following booster injections.**
- 3. Beyond any doubt, injection of gene-based COVID-19 vaccines place lives under threat of illness and death.**
- 4. We note that both mRNA and vector-based vaccines are represented among these cases, as are all four major manufacturers.**

² Bhakdi and Burkhardt, On COVID vaccines: why they cannot work, and irrefutable evidence of their causative role in deaths after vaccination. Transcript from Live Streamed presentations at the Doctors for COVID Ethics Symposium December 10, 2021.